



A Simplified Method of Centric Relation Record

Saafi J*, Chebil M M , Debbabi I, Jabnoun N

Faculty of Dental Medicine, University of Monastir, Tunisia

Abstract

The definition of CR has evolved over the years into the most controversial subjects than any other dental concept in dentistry. This ranges from a retruded posterior position, to superior position and then to an anterior superior position. Recording the centric relation is the most crucial step for obtaining a prosthesis with an occlusion entirely in harmony with the stomatognathic system. We used an direct interocclusal record in which is the oldest type of Centric Relation record. This physiologic method needs normal functioning of the patient's proprioception and the tactile sense in order to make an accurate record. In our technique interocclusal wax was used to record maximum intercuspation (MI) followed by recording centric relation (CR) to obtain a reproducible mandibular position in a dentulous subject

Abbreviations: CR: centric relation, MI: maximum intercuspation CCR: centric relation, MI: maximum intercuspation R: centric relation, MI: maximum intercuspation

Keywords: Centric Relation, Maximum Intercuspation, Record, Wax, Chin Point Guidance

Corresponding author: Prof.Saafi Jilani

Faculty of Dental Medicine, University of Monastir, Tunisia.

E mail: saafi_jilani@yahoo.fr

Citation: Saafi Jilani et al. (2018), A Simplified Method of Centric Relation Record. Int J Dent & Oral Heal. 4:6, 77-83

Copyright: ©2018 Saafi Jilani et al. This is an open-access article distributed under the terms of the Creative Commons Attribution License, which permits unrestricted use, distribution, and reproduction in any medium, provided the original author and source are credited

Received: May14, 2018

Accepted: May 22, 2018

Published: June 08, 2018

Introduction:

Centric relation (CR) has been considered a maxillomandibular position of choice for some dental and prosthetic procedures. Although regarded as a fully reproducible relation, there is a great controversy about its clinical use and recording technique [1]. H.T shillingburg in 2012 defined Centric relation 'centric relation, is an anteriorly, superiorly braced position along the articular eminence of the glenoid fossa, with the articular disc interposed between the condyle and eminence. [2,3] Centric relation: the maxillomandibular relationship in which the condyles articulate with the thinnest avascular portion of their respective disks with the complex in the anterior superior position against the shapes of the articular eminencies. This position is independent of tooth contact this position is clinically discernible when the mandible is directed superior and anteriorly it is restricted to

a purely rotary movement about the transversal horizontal axis (GPT-8) (Glossary of prosthodontic terms) The indications of recording in centric relation is to perform an occlusion analysis, in fixed denture prosthesis for long span bridge, in removable denture prosthesis when there is a loss of vertical dimension and, obviously in complete removable denture prosthesis [4,5]

The different methods of recording relations centric are classified mainly as below: direct recording, graphic recording, functional recording and cephalometrics: [6] Semi adjustable articulators are commonly used in restorative dentistry, especially in prosthodontics for their simplicity in handling and programming [7]. The direct interocclusal record where a patient's jaw relationship is recorded with a thermoplastic or a self-hardening recording medium interposed between the maxillary and mandibular teeth as the mandible hinges closed [8,9]

Materials and Methods:

There are five techniques of CR registration:

Roth power centric bite:

This technique uses two steps: In the first step and after placing the heated wax (Bite Registration Sheet Wax, Almore Int. Inc., Portland, Oregon) in the subject's mouth, the subject was instructed to put their tongue to the roof of their mouth and relax their lower jaw while the operator, holding the mandibular symphysis, guided the lower incisors into the wax. Next, the subject was instructed to close their posterior teeth into the wax. When the cusp tips of the lower posterior teeth had impressed the wax, the subject was instructed to stop. In the next step, after removal from the subject's mouth, the anterior portion of the wax wafer was hardened in an ice water bath followed by flame heating the posterior portions of the wax wafer. The wax was returned to the mouth and the subject instructed to "bite and hold" into the hard anterior stop, allowing the posterior teeth to embed in the soft posterior wax. The posterior wax was cooled with air from an air/water syringe and removed. After it had cooled, the bite was checked intra-orally for accuracy.

Tongue tip to soft palate:

The subject was instructed to touch their tongue as posteriorly as possible to their soft palate while slowly closing into a registration material to obtain an interocclusal record using the Tongue Tip to Soft Palate Technique

Chin point guidance:

In this technique, the operator grasped the chin and guided the subject's mandible into the registration material which was allowed to set before removing it from the subject's mouth

Bimanual manipulation:

The Bimanual Manipulation Technique was performed by placing both of the operator's hands under the subject's mandible. Slight superior pressure was applied at the gonial angle and inferior pressure at the mandibular symphysis, guiding the mandible into registration material. This registration material was allowed to harden and removed from the subject's mouth

Leaf gauge:

To obtain an interocclusal record using the Leaf Gauge Technique, a

sufficient number of soft plastic leaves gauge was placed between the subject's maxillary and mandibular incisors to provide sufficient vertical dimension to just disocclude the posterior teeth. The subject is sitting upright for 5 minutes in this situation. The subject was then placed in a supine position, the registration material was applied to the occlusal surfaces of the mandibular teeth after removing the leaf gauge without allowing any occlusal contact. The leaf gauge was then replaced, as an anterior stop, and the subject instructed to close into the registration material in the previous position. The registration material was allowed to set and then removed from the patient's mouth. [9]

In our study the method used for recording CR is a technical report: The record of centric relation is always preceded by mounting of the maxillary cast on articulator. In this clinic case we used a semi adjustable non arcon, the Quick "Lab" (Mounting Stone, Whip Mix, Louisville, Kentucky) (Figure 1) which was adjusted with condylar inclination set at 20° to 40° (mean 30°) and Bennett angle at 15°

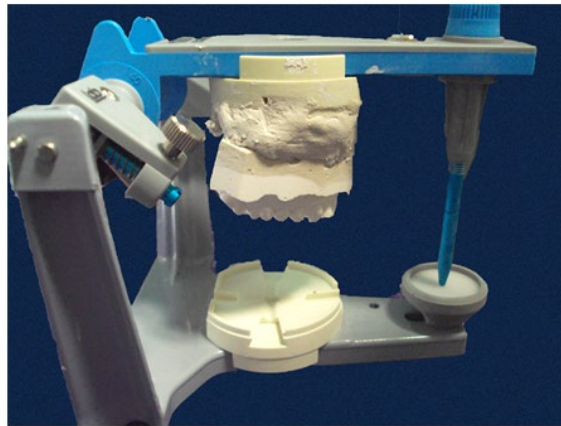


Figure 1: Semi adjustable non arcon with maxillary cast

In our method, the patient must be trained and guided to the movements of opening and closing in order to permit muscle relaxation. (Figure 2)

Materials and methods:

Heat-retaining wax sheet (i.e., Moycowa; Moyco industries; Philadelphia; USA) Record wax (i.e., Aluwax wax; Aluwax dental product co Grand rapids, Michigan; USA) Ice water

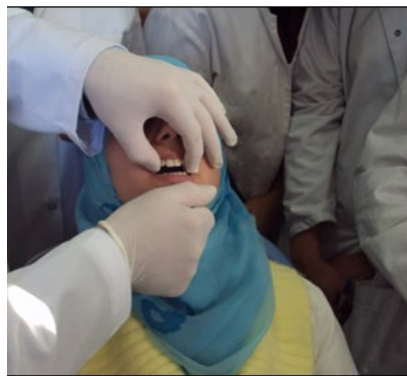

Figure 2: Training of the patient by opening and closing movements

-Soften uniformly a strip of wax (Moyco wax) in warm water ($T = 52^{\circ}$) (figure 3) then, adapt by pressing slightly on the maxillary cusp tips of maxillary cast (Figure 3)



Figure 3: strip of wax (Moyco wax) Soften in warm water

Cut, using scissors, wax still softened to the dimensions of the maxillary on buccal cusps and incisor edges (figure 4& 5):

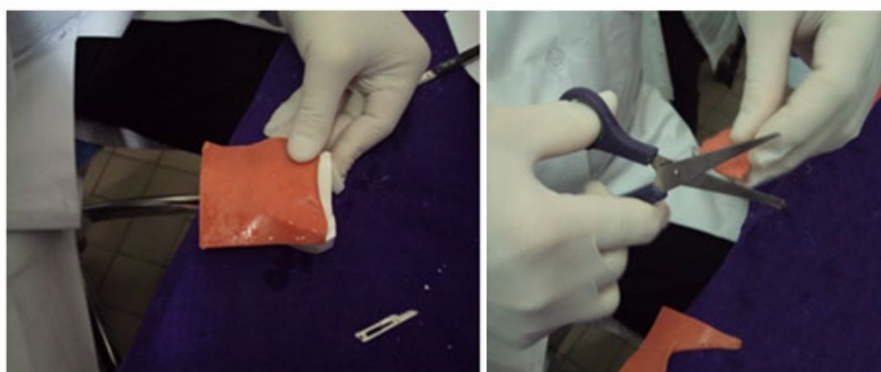

Figure (4& 5): Wax (Moyco) is adapted on the maxillary cusp tips and cutted

Reduce the thickness of the wax by using a scalpel until a thickness of 2 mm. This reduction should save sectors of wax related to the prepared

antagonist or beyond teeth (presence of already occlusal clearance of prepared teeth) because more thickness is needed (Figure 6)



Figure 6: reduction of the thickness of the record wax

Adapt the recording wax or "check bite" (strip of moyco wax) to the maxillary jaw and guide the patient's mouth voluntarily into maximum

intercuspatation (MI) and make cuspal indentations of the mandibular teeth tips (2 anterior and 2 posterior) (Figure 7).




Figure 7: strip Wax record with the mandibular teeth tips indentations after guiding the patient into MI (see arrows).

reline the indentations tips with droplets of 2mm diameter of a recording wax (i.e., Aluwax used in our method) (Figure 8) or with a temporary sealing quick setting cement (i.e., Temp Bond) and manipulate the mandible to guide the patient's mouth into CR. This

approach is based on the fact that usually there is in most patients a sagittal shift between MI and the CR (means 0.5 mm). Thus , when the patient is guided in CR , some indentations of mandibular incisor edges and molar cusp tips will be logically engraved in the wax (i.e., Aluwax) or in temporary sealing cement




Figure 8: Relining of the indentations with the wax (i.e., Aluwax) -Seat the patient in the orthostatic position

Maintains his left cheek with the left index finger guide with the right hand the mandible with thumb folded in front of his chin, and index folded underneath guide the patient, in centric relation, and ask him to gently shallow indentations in record wax by two or three movements of closing (Figure 9)

The resulting relaxation allows the practitioner, in one swift motion opening and then closing, to exceed the possible neuromuscular reflexes and to indent the wax more deeply. Repeat several times this operation to ensure reproducibility and take care that the record should be dried before any adding of new wax.

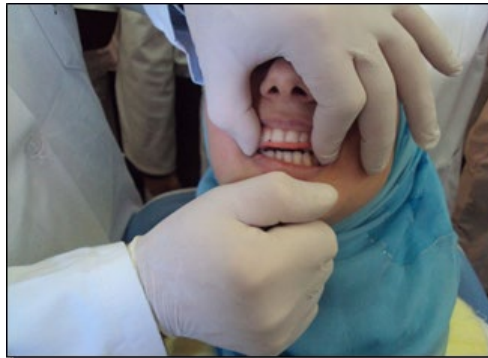

Figure 9: (chin point guidance) or unimanual mandibular method to guide the patient into CR

After wax chilling in ice water, until the indentations become hard, recheck the perfect adaptation among the indentations engraved in Aluwax wax and the cusps tips of the corresponding teeth (Figure 10)

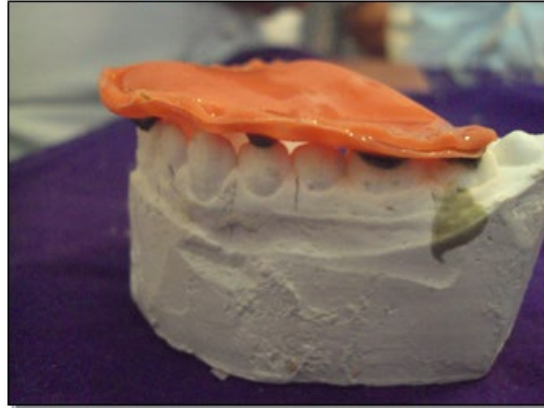

Figure 10: Verification of the adaptation of the indentations of Aluwax wax with the indentation cusps tips of the corresponding teeth

Mounting the mandibular cast:

Adjust the incisal guide pin to 2mm (which corresponds to the thickness of the wax record). Then place the mandibular cast oriented on the

CR record and check the correspondence of mounting patterns on articulator with the clinical situation. apply mounting stone to the mandibular cast and the mounting plate (Figure 11)

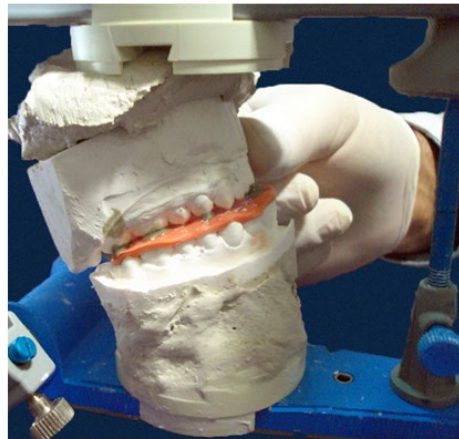


Figure 11: Mounting the mandibular cast

Evaluation :

We use a method described by Rosentiel, Land and Fujimoto to assess the accuracy of this method of CR record and to compare the tooth contacts on the casts with those in the mouth. During the clinical examination, the position of tooth contacts in CR can be marked with thin articulating film. Normally, the markings are on the mesial inclines of maxillary cusps and the distal inclines of mandibular cusps. Their exact location can be transferred by having the patient close through thin occlusal indicator wax. The articulated casts are closed, and the retruded tooth contacts marked with articulating film. When the indicator wax is transferred to the casts, the perforations should correspond exactly to these marks.^[10]

Discussion:

The definition of CR has been changing repeatedly and till date there does not seem to have any consensus about it. The old definitions of CR had taken account only of the position of the head of the condyle in the glenoid fossa. The head of the condyle, articular disk, glenoid

fossa, slopes (shapes) of articular eminence of temporal bone... etc are clinically invisible parts because no one <<has seen >> one day these articular structures when recording CR, but we can only see and manipulate the mandible. thus, there was most confusing controversial part of this position and that why CR definition has changed over the past century from being a posterior superior position of the condyle in relation to the glenoid fossa to an anterior superior position^[11]

Regarding the methods of mandibular manipulation and according to H.T Shillingburg the most consistent, repeatable results can be accomplished using the technique of "bimanual manipulation" described by Dawson.^[12, 13]

Mc Collum^[14] and Granger^[14] stated that Centric Relation is that position where the mandible rotates around the hinge axis. In securing maxillo-mandibular records, both investigators recommended the use of chin point guidance recommended by Gutchet in 1970 in retruding the mandible. Others who advocated this technique include Kornfeld,^[15] Thompson,^[16] Aull,^[17] and Sloan.^[18] The Bimanual Manipulation

Technique was touted as highly repeatable, but also the most technique sensitive [16,19]. The Roth Power Bite Technique was found to be repeatable, but was criticized as not physiologic [20,21].

Other techniques of recording CR such as Chin Point Guidance, Swallowing, and Tongue Tip to Soft Palate have produced more variable results [22, 16, and 23]. A study conducted by Adam L. Swenson and Al. to determine Condylar positions generated by five centric relation recording techniques concluded that The Roth Power Bite and Leaf Gauge Techniques positioned condyles slightly more anterior and superior than the other techniques [24]. In another study conducted by Nikolina Holen Galeković and all concluded that bimanual manipulation, chin point guidance and Roth's method are clinical CR registration techniques of equal accuracy and reproducibility in asymptomatic subjects with normal occlusal relationship [25].

Nevertheless, since many years, in our faculty of dental medicine we use an unimanual method (chin point guidance), described by Lauritzen because it is a very fast technique and enables to avoid the neuromuscular reflexes during centric relation recording with suitable accuracy. On another hand, this method, compared to the bimanual one, when learned to students in our faculty of dentistry, it has been easily understood and practiced.

More than 20 years of clinical practice I use this method of mandibular manipulation with safety and accuracy, which allow to give us a clinical sensation of a perception and repetitive retruded mandibular position followed by mandibular rotation so a condyle rotation. The rotational movement is limited to about 12mm of incisor separation before the temporomandibular ligaments and structure anterior to the mastoid process force the mandible so the condyle to translate by contraction of the lateral pterygoide muscle which moves the condyle-disk coapted forward the along the posterior incline of the tubercle [19]. One of the biggest misunderstandings seen, is the tendency for dentists to think CR is achieved by forcing the jaw back to seat the condyles [26]. Moreover, the CR should be related to a vertical dimension. That's why in complete removable denture prosthesis the CR record is always related to a vertical dimension predetermined. According to Asch the position has been difficult to define anatomically but is determined clinically by assessing when the jaw can hinge on a fixed terminal axis (up to 25 mm). In our technique we used a recording wax of maximum 3mm thickness (Moyco wax and Aluwax) which enables the condyle to reach the position of CR. The non coincidence between CR and MI is likely different among authors (Posset: 85%, Hansson: 3%, Rosenweig: 100%).

When the mandible is guided in MI the number and the location of indentations teeth tips are easily verified prior to CR record. The indentation of teeth tips recorded in Moyco wax in MI and, when relined in CR with small amount of Alumax wax (dimensions are almost 2mm of diameter), the new shallow indentations will be made anyway there is or not coincidence between CR and MI. The disadvantage of this technique is that the patient, being guided in MI, could have memorized this position which can result a difficult guide in CR and can distort the record in CR. Clinically, a technique that provides fidelity and reproducibility of the CR is essential. [27]

A study conducted in the faculty of dentistry of Monastir (Tunisia) to evaluate the accuracy of our technique using Rosenstiel and al. method found 90% coincidence among tooth contacts on the casts with those in the mouth after CR records.

Accurate mounting of casts depends on precise manipulation of the patient's mandible by the dentist. The ease with which this can be accomplished depends on the degree of the patient's neuromuscular relaxation and on sound technique. Thus, in turn, it depends on the patient's permitting the dentist to control the mandible because it is

a patient-passive technique which require the dentist's assistance [10]

Conclusion:

Currently, a consensual definition of CR described in the literature refers to a reproducible physiological position that is independent of occlusal contacts [28].

CR is used in dentistry as repeatable reference position for mounting casts on an articulator for performing occlusal analysis, in complete removable denture, and in many clinical cases in partial denture prosthesis and in fixed denture prosthesis. Our method, comparable to other techniques is more likely to be easy and uses fewer materials. Simple in appearance, it needs more accuracy and relatively reduced chairside time.

References:

- Evelyn M K, Luis FRL, Melissa TK, Fernando T (2003) [Centric relation registration: intra- and interexaminer agreement after a calibration program](#) *Pesqui Odontol Bras*;17(3):286-91
- Nomenclature Committee of the Academy of Denture Prosthetics (1987) *Glossary of Prosthodontic Terms*, ed 5. St Louis: Mosby,;15.
- Herbert T. Shillingburg Jr. ... [et al.]. (2012) 4th ed. *Fundamentals of fixed prosthodontics*
- Ramfjord SP, Ash MM Jr(1995) *L'occlusion*. Philadelphia: WB Saunders Co.,.
- Gilboe DB (1983) centric relation as the treatment position. *J Prosthet Dent*;50:685-
- Nidhi D, Poonam K, Amardeep ,Vishavpreet S (2017) [Meta-Analysis of Various Methods of Recording Centric Jaw Relation- A Literature Review](#) *International Journal of Health Sciences & Research* 349 Vol.7; Issue: 3
- Nooji D (2008) [The third point of reference and its effect on the pryrusive condylar guidance angles obtained in semiadjustable articulator.](#) *J Indian Prosthodont Soc* 8(2):71-77
- Smith HF, Jr. (1975) [A comparison of empirical centric relation records with location of terminal hinge axis and apex of the gothic arch tracing.](#) *J Prosthet Dent.*; 33:511-20.
- Myers ML. (1982) [Centric relation records-historical review.](#) *J Prosthet Dent.*; 47:141-5
- Rosenstiel Land.Fujimoto(2006) *contemporary fixed prosthodontics* ISBN-13: 978-0-323-02874-5 ISBN-10: 0-323-02874-8 tome 1
- Jayant N. Palaskar, R. Murali, Sanjay Bansal (2013) [Centric Relation Definition: A Historical and Contemporary Prosthodontic Perspective](#) *J Indian Prosthodont Soc. Sep*; 13(3): 149-154.
- Weinberg LA. (1960) [Physiologic objective of reconstruction techniques.](#) *J Prosthet Dent*;10:711-724
- Schuyler CH. (1963) [The function and importance of incisal guidance in oral rehabilitation.](#) *J Prosthet Dent*;13:1011-1030
- Granger ER. (1952) [Centric relation.](#) *J Prosthet Dent*;2:160-71.
- Kornfeld M. (1955) [Problems of function in restorative dentistry.](#) *J Prosthet Dent*;5:670-76.
- Kantor ME, Silverman SI ,Garfinkel L. (1972) [Centric-relation recording techniqu es--a comparative investigation.](#) *J Prosthet Dent.*; 28:593-600.
- Aull AE. (1963) [A study of transverse axis.](#) *J Prosthet Dent*;13:469-79
- Sloan RB. (1952) [Recording and transferring the mandibular axis.](#) *J Prosthet Dent*;2:172-81.
- Wood DP and Elliott RW. (1994) [Reproducibility of the centric relation bite registration technique.](#) *Angle Orthod.*; 64:211-20.
- Utt TW, Meyers CE, Jr., Wierzbza TF ,Hondrum SO. (1995) [A threedimensional comparison of condylar position changes between centric relation and centric occlusion using the mandibular position indicator.](#) *Am J Orthod Dentofacial Orthop.*; 107:298-308.

21. Schmitt ME, Kulbersh R, Freeland T, Bever K, Pink FE. (2003) Reproducibility of the Roth power centric in determining centric relation. *Semin Orthod.*; 9:102-108
22. Campos AA, Nathanson D and Rose L. (1996) Reproducibility and condylar position of a physiologic maxillomandibular centric relation in upright and supine body position. *J Prosthet Dent.*; 76:282-7.
23. Simon RL and Nicholls JI. (1980) Variability of passively recorded centric relation. *J Prosthet Dent.*; 44:21-6.
24. Swenson AL, Oesterle LJ, Shellhart WC, Newman SM and Minick G. (2014) Condylar positions generated by five centric relation recording techniques. *Oral Biol Dent.*; 2:8.
25. Nikolina HG, Vesna F, Vedrana B, Robert Č (2017) Reproducibility of Centric Relation Techniques by means of Condyle Position Analysis *Acta Stomatol Croat.* ; 51(1): 13–21.
26. Edward C. Jarvis D. (1963) A method of recording centric relation *The Journal of Prosthetic Dentistry* Volume 13, Issue 4.; 617-621 [https://www.thejpd.org/article/0022-3913\(63\)90132-X/abstract?code=ymp-site](https://www.thejpd.org/article/0022-3913(63)90132-X/abstract?code=ymp-site)
27. Fernanda P, Wilkens Aurélio B e S, Frederico A e S, Guilherme da G R, Mônica V de J C (2007) Evaluation of the reproducibility of tow techniques used to determine D and record centric relation in Angle's class 1 patients. *Appl Oral Sci.* 15(4): 275–279.
28. Keshvad A, Winstanley R B. (2001) An appraisal of the literature on centric relation. Part III. *J Oral Rehabil.*; 28(1):55–63.