



## Salivary Duct Carcinoma of the Parotid: Rare Entity

Garima Rawat<sup>\*2</sup>, Anshuman Kumar<sup>1</sup>

<sup>1</sup>MBBS, MS (Surgery), MRCS (Edinburgh) U.K., M.Ch (Oncosurgery), Director – Surgical Oncology, Dharamshila Narayana SS Hospital, Delhi, India

<sup>2</sup>BDS, MDS (Oral & Maxillofacial Pathology) Research Fellow, Department of Head & Neck Oncology Dharamshila Narayana SS Hospital, Delhi, India

### Abstract

Salivary duct carcinoma (SDC) is a highly aggressive malignant salivary gland tumor. It can arise as a carcinoma de novo or it may constitute the malignant component in carcinoma ex pleomorphic adenoma. This tumour microscopically resembles high-grade ductal carcinoma of the breast, with both in situ and invasive patterns. Here, we discuss a case of Salivary duct carcinoma (SDC) of the parotid gland in a 67-year-old male with emphasis on its surgical management and adjuvant therapies

**Keywords:** Salivary Duct Carcinoma, Necrosis, Parotid Gland, Ductal Carcinoma Breast

### Corresponding author: Garima Rawat

M.D.S, Research Fellow, Department of Head & Neck Oncology, Dharamshila Narayana SS Hospital, Delhi, India. Tel: +-91-9873776634,

E-mail: [garima3103@gmail.com](mailto:garima3103@gmail.com)

**Citation:** Garima Rawat et al. (2018), Salivary Duct Carcinoma of the Parotid: Rare Entity. Int J Dent & Oral Heal. 4:4, 50-53

**Copyright:** ©2018 Garima Rawat et al. This is an open-access article distributed under the terms of the Creative Commons Attribution License, which permits unrestricted use, distribution, and reproduction in any medium, provided the original author and source are credited

**Received:** March 19, 2018

**Accepted:** March 29, 2018

**Published:** April 11, 2018

### Introduction

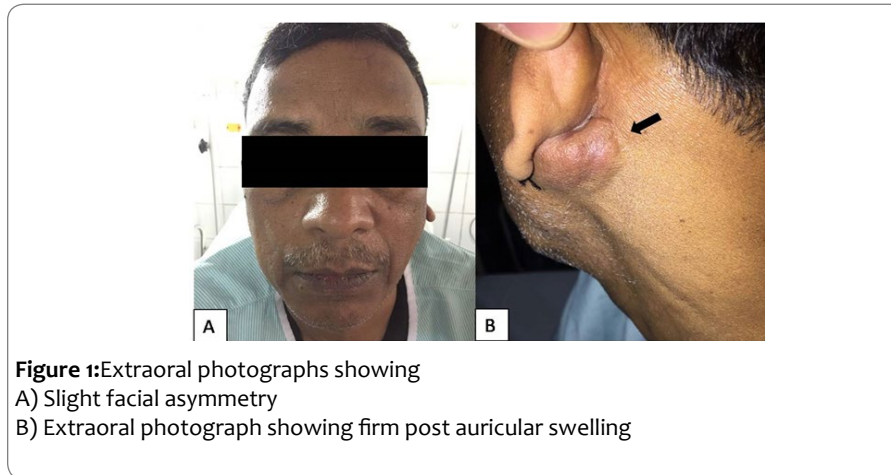Salivary gland cancers (SGCs) are relatively rare, accounting for 1-6% of all neoplasms of the head and neck region, and these neoplasms are diverse with respect to origin and pathology. According to Ellis and Auclair, salivary gland cancers usually develop in the major salivary gland ie parotid gland in around 75% cases of which only about 20% are malignant while 15% are located in minor salivary glands. Only, 10% arise in the submandibular glands, and less than 1% presents in the sublingual glands. Salivary duct carcinoma (SDC) was first

recognized by Kleinsasser and colleagues in 1968<sup>1,3</sup>. It is a relatively uncommon, clinically aggressive adenocarcinoma of salivary origin that is histologically similar to carcinoma of the breast. The usual demographic profile is that of adult males over 50 years of age. The aggressive biologic behavior of SDC is evident in rapid clinical growth and associated symptoms of facial nerve infiltration<sup>4</sup>.

Here we present a case of SDC involving the parotid gland in a 67-year-old male with emphasis on the surgical management and adjuvant therapies.

### Case Report

A 67 year old male patient reported to the outpatient department of a tertiary care hospital with the chief complaint of swelling in the left post auricular region since 7 months. The swelling was initially small in size and gradually increased in size over a period of 7 months to its present size. The swelling was associated with mild pain, which was intermittent in nature and relieved on taking medication. Patient consulted at AIIMS for the same where he underwent Ultrasound (USG) guided Fine Needle Aspiration Cytology (FNAC) from the left post auricular swelling. The cytopathology findings were suggestive of poorly differentiated adenocarcinoma. The patient was prescribed contrast enhanced computed tomography (CECT) of neck which showed soft tissue mass involving superficial and deep lobe of left parotid gland. From there, patient was referred to our hospital for management of the same. Patient was a known Diabetic taking Oral hypoglycemic drugs since years. Personal history was non contributory. Extraorally, on inspection swelling measuring 4 x 3cm in size was evident in the left post auricular region raising the left ear lobe, it was irregular in shape and the overlying skin was normal. Intraoral inspection revealed no abnormality. On palpation, the swelling was bony hard, slightly tender, nodular and fixed to underlying muscles and measuring approximately 4 x 3cm in size (Fig 1A,B).

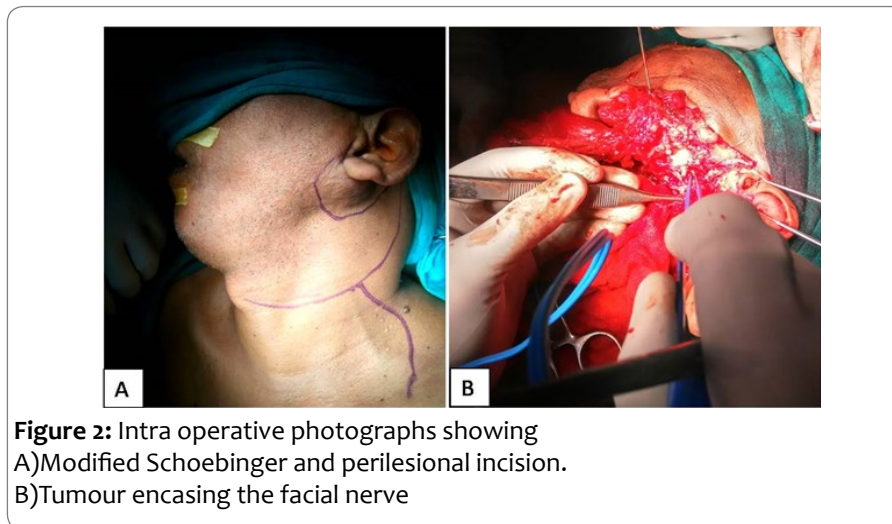


**Figure 1:** Extraoral photographs showing  
 A) Slight facial asymmetry  
 B) Extraoral photograph showing firm post auricular swelling

It was covered with normal skin, raising the ear lobe and afebrile to touch. On examination, nerve functioning was normal. On stimulation of salivation, the salivary flow from the stenson's duct was normal. On lymph node examination, no lymph nodes were palpable. Patient was advised further PET scan, findings off which were suggestive of a metabolically active soft tissue mass at left intra-auricular region in the left parotid gland (superior lobe) measuring approximately 3.3 x 3.4 x 2.4 cm, abutting the left sternocleidomastoid muscle. (Fig 2) In order to rule out metastasis, PET scan was also done. There was no evidence of any distant metastasis.

Based on clinical, cytopathology and imaging findings, a final diagnosis

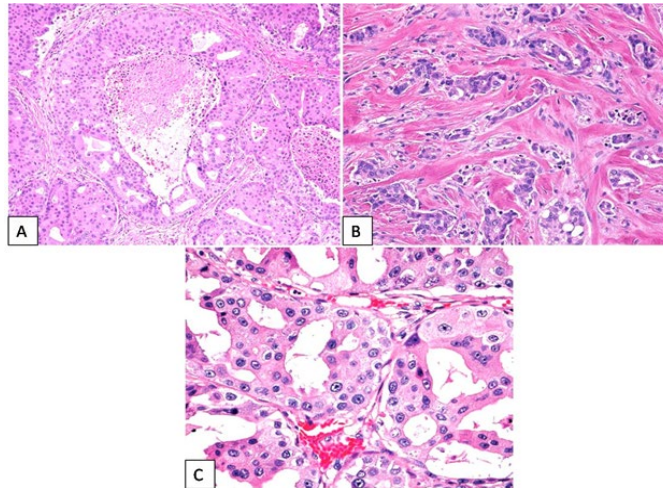
of poorly differentiated adenocarcinoma of the parotid gland was made. It was planned for left radical parotidectomy and left modified neck dissection along with lateral canthoplasty of left eye. The patient was operated under general anesthesia after giving a modified Schoebinger's incision (Fig. 2A) and raising the flaps. Left modified neck dissection type II was performed preserving the Internal juglar vein (IJV) and spinal accessory nerve (SAN). After this, a perilesional incision (Fig. 2A) was given around the left parotid mass and flaps were raised. Radical parotidectomy was carried out removing the facial nerve (Fig. 2B) and the adjacent overlying skin. Hemostasis was achieved and lateral canthoplasty of left eye was done.



**Figure 2:** Intra operative photographs showing  
 A) Modified Schoebinger and perilesional incision.  
 B) Tumour encasing the facial nerve

Gross examination of the excised specimen of parotidectomy showed grey white tumour that had obliterated the lobules of parotid gland with preservation of parotid tissue only at the upper pole. The histopathological examination of the parotidectomy specimen revealed the tumour composed of atypical cells arranged in cribriform

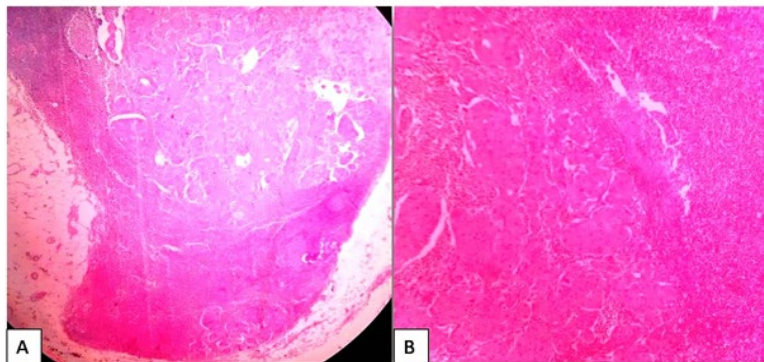
pattern, glands, tubular structures and cords. The central portion of the cell clusters showed comedo-like necrosis (Fig 3A). The stroma shows areas of desmoplasia (Fig 3B). Periphery shows infiltrative margin with some areas showing broad fronts.. The tumour cells show pleomorphic vesicular nuclei, nucleoli and moderate eosinophilic cytoplasm (Fig 3C).



**Figure 3:** Photomicrographs of main tumour showing  
 A) Cribriform pattern of tumour with central necrosis  
 B) Extensive areas of stromal desmoplasia  
 C) Tumour cells showing vesicular pleomorphic nuclei

Areas of perineural invasion and multiple foci of lymphovascular invasion were observed. Three out of the twenty eight lymph nodes dissected showed metastatic deposits without any extra nodal

extension (Fig. 4A, B). Immunohistochemistry markers were used which comprised of HER-2 neu, CEA, and c-erd-B2. The tumour cells expressed immunopositivity for HER-2 neu. Thus, a final diagnosis of salivary duct carcinoma was made with stage as pT4aN2b.



**Figure 4:** A,B- Photomicrographs showing lymph nodes with metastatic deposits of tumour

After one week post surgery, the patient was examined and satisfactory healing of surgical site was evident. Patient was referred to Department of Chemotherapy and Radiotherapy where it was planned to carry out concurrent chemotherapy and adjuvant radiotherapy. Patient underwent Carboplatin based concurrent chemotherapy which the patient tolerated well. After completion of chemotherapy, the patient underwent 6 cycles of radiotherapy. Patient is kept under regular follow up initially at an interval of 2 months upto 1 year.

### Discussion

Salivary gland neoplasms comprise a diverse group of tumors with varied histological characteristics and clinical behavior patterns. Salivary gland neoplasms show infiltrative behavior and late loco-regional recurrence and distant metastasis, these mandate a proper diagnosis and treatment<sup>5</sup>. Salivary duct carcinoma (SDC) is a rare salivary gland

neoplasm which represents 0.2% to 2% of parotid tumors<sup>2</sup>. The tumor occurs in elderly men, generally in the fifth to sixth decade of life and predominantly in the parotid gland. Our case also the patient was a male of slightly higher age ie in the seventh decade.

Majority of the cases of SDC present as a rapidly enlarging firm mass accompanied by facial paralysis or pain<sup>6,7</sup>. In the current case, patient presented with a mildly tender swelling of 7 months duration although there was no facial nerve paralysis.

Cervical adenopathy and lymph node invasion are identified in 35% and 40- 80% of SDC patients respectively<sup>3</sup>. However, in the present case study, no lymph nodes were observed but three lymph nodes demonstrated histopathological involvement.

Systemic metastases are very common and are directed primarily to the lungs and bones, other sites include liver, thyroid gland, brain, skin and the inguinal lymph node. Fortunately, no such metastatic deposits



were reported in our case at the time of surgery.

SDC is thought to be a distinct malignancy of the major salivary glands because of its highly aggressive behavior and resemblance to ductal carcinoma of the breast.

The tumor may arise de novo or in a pleomorphic adenoma (salivary duct carcinoma ex pleomorphic adenoma). Most vary from a few millimeters up to 7 cm and on cross section are gray-white to yellow-tan with borders that range from well to poorly defined. Some have a uniform, firm solid appearance, and others have both solid and cystic components.

Histologically, it shows a striking resemblance to breast carcinoma of the ductal type, presenting intraductal and invasive components. Intraductal component comprises of expanded salivary ducts with solid, papillary, "Roman bridge", cribriform and comedo patterns ie central portion of the ductal cell nests undergoes comedo-like necrosis. The Infiltrating component includes a mixture of small ducts, cribriform structures, small nests of cells and trabeculae, all accompanied by stromal desmoplasia. Perineural and lympho-vascular invasion are frequently observed. The tumour cells contain moderate amounts of eosinophilic granular cytoplasm with vesicular nuclei having coarse chromatin with prominent central nucleoli. Frequently, there is marked nuclear pleomorphism also. Dystrophic calcification may also be seen sometimes, which masquerades as calculi. Variants of SDC include invasive micro papillary variant, sarcomatoid variant, intraductal carcinoma.

SDC is considered to have one of the worst short-term prognoses. The markers that have been studied include Ki-67, proliferating cell nuclear antigen, c-erbB-2 and p53.12 Protein-15 and androgen receptor (AR) are frequently positive in this tumor. The estrogen receptor and progesterone receptor are not detected in most SDC and they help to differentiate the metastasis from the breast. Prostate-specific antigen is occasionally detected in this tumor.

The mainstay treatment for SDC's is complete surgical resection, with adequate free margins. Elective treatment of the No neck is a controversial topic. Our patient underwent radical parotidectomy along with left modified neck dissection type II owing to the aggressive tumour behaviour, recurrent tendencies and abutment to the left sternocleidomastoid muscle.

Postoperative radiotherapy (PORT) can be used as an adjuvant therapy in patients with high-risk factors. However, about the efficacy of chemotherapy for advanced SDCs is not much researched due to the rarity of the disease. Till date selecting the effective therapeutic pathway for patients with recurrent tumors and those with unresectable or metastatic cancer is a great challenge<sup>9</sup>. Authors in the past have compared the disease free survival period of patients who underwent alone surgery or surgery in combination with adjuvant therapies. These authors found significantly improved survival rates in patients undergoing surgery followed by post operative radiotherapy. Chemotherapy has been said to be useful as a palliative treatment for patients with symptomatic locally recurrent and/or metastatic disease which were not amenable to further surgery or radiation. A

platinum-based chemotherapy regimen can be beneficial to patients with incurable SDCs, especially for symptomatic or rapidly progressive patients<sup>9</sup>. However, in the current case due to the close proximity of tumour to overlying skin (0.1cm), multiple foci of lymphovascular invasion and perineural invasion, presence of comedo necrosis and pathological stage being pT4aN2b it was planned for carboplatin based concurrent chemotherapy and adjuvant radiotherapy. Zainab et al also have used chemotherapy and radiotherapy post surgery in their case<sup>10</sup>.

SDC is a very aggressive tumour with worst prognosis. Most patients die of their disease within 4 years of diagnosis. Prognosis is better in tumors measuring less than 2 cm. The incidence of local recurrence, cervical lymph node metastases, and distant metastases are, respectively 33%, 59%, and 46%.1-3

## Conclusion

SDC of should be treated aggressively along with adjuvant therapies with the aim of achieving negative surgical margins in order to prevent recurrence. Also, patient should be adequately followed up to monitor distant metastasis and recurrence.

## References

1. Mlika M, Kourda N, Zidi YSH, Aloui R et al. Salivary duct carcinoma of the parotid gland. *J Oral Maxillofac Pathol.* 2012; 16(1): 134-136.
2. Y. Pons, A. Alves, P. Clément, C. Conessa. Salivary duct carcinoma of the parotid. *European Annals of Otorhinolaryngology, Head and Neck diseases.* 2011;128:194—196.
3. Jamal AM, Sun ZJ, Chen XM, Zhao YF. Salivary duct carcinoma of the parotid gland: case report and review of the literature. *J Oral Maxillofac Surg.* 2008 Aug;66(8):1708-13.
4. Kinnera VSB, Mandyam KR, Chowhan AK, Nandyala R, Bobbidi VP, Vutukuru VR. Salivary duct carcinoma of parotid gland. *Journal of Oral and Maxillofacial Pathology : JOMFP.* 2009;13(2):85-88.
5. Xie S, Yang H, Bredell M, et al. Salivary duct carcinoma of the parotid gland: A case report and review of the literature. *Oncology Letters.* 2015;9(1):371-374.
6. Simpson RH. Salivary duct carcinoma: new developments—morphological variants including pure in situ high grade lesions; proposed molecular classification. *Head Neck Pathol.* 2013 Jul;7 Suppl 1:S48-58.
7. Gilbert MR, Sharma A, Schmitt NC, Johnson JT, Ferris RL, Duvvuri U et al. A 20-Year Review of 75 Cases of Salivary Duct Carcinoma. *JAMA Otolaryngol Head Neck Surg.* 2016 May 1;142(5):489-95.
8. Moriki T, Ueta S, Takahashi T, Mitani M, Ichien M. Salivary duct carcinoma: cytologic characteristics and application of androgen receptor immunostaining for diagnosis. *Cancer.* 2001 Oct 25;93(5):344-50.
9. Wang X, Luo Y, Li M, Yan H, Sun M, Fan T. Management of salivary gland carcinomas - a review. *Oncotarget.* 2017;8(3):3946-3956.
10. Zainab H, Sultana A, Jahagirdar P. Denovo High Grade Salivary Duct Carcinoma: A Case Report and Review of Literature. *Journal of Clinical and Diagnostic Research : JCDR.* 2017;11(7):ZD10-ZD12.