



## Interproximal Reduction in Orthodontics: A literature review

Shikha Rastogi<sup>1</sup>, Ashish Gupta<sup>2</sup>

<sup>1</sup>Consultant Orthodontist, Faridabad, Haryana, India

<sup>2</sup>Consultant Esthetic Dentist, Agra, Uttar Pradesh, India

### Abstract

One of the basic principles of Orthodontics is the creation of space to facilitate tooth movement. With appropriate case selection, interproximal reduction offers the ability to safely obtain sufficient space for tooth movement without the need for extractions and without compromising slenderized teeth.

**Keywords:** Slenderization, Space gain, Proximal stripping, Tooth contouring

### Corresponding author: Shikha Rastogi

Consultant Orthodontist, Faridabad, Haryana, India. Tel: 08126934458

E mail: [drshikharastogi@gmail.com](mailto:drshikharastogi@gmail.com)

**citation:** Shika Rastogi (2018), Interproximal Reduction in Orthodontics: A literature review. *Int J Dent& Oral Heal.* 4:10, 164-172

**Copyright:** ©2018 Shikha Rastogi. This is an open-access article distributed under the terms of the Creative Commons Attribution License, which permits unrestricted use, distribution, and reproduction in any medium, provided the original author and source are credited

**Received:** August 23, 2018

**Accepted:** August , 2018

**Published:** October 06, 2018

### Introduction

Creating space to facilitate tooth movement is one of the basic principles of Orthodontics. As patients seek faster orthodontic treatment, extraction is becoming reserved for cases where there is severe crowding, a need for vertical change or control, or where sagittal correction/compensation cannot otherwise be accomplished. For less severe cases there has been an increasing trend towards expansion or interproximal reduction (IPR), with the choice depending on the case. IPR is also known as enamel reduction, stripping, or interproximal reduction<sup>1</sup>.

### Historical Perspectives

The natural interproximal abrasion of teeth was discussed by Black in 1902.<sup>2</sup> Since then; numerous studies have addressed interproximal abrasion and reduction. In 1944, Ballard<sup>3</sup> described the interproximal reduction technique for the first time. Sheridan<sup>4</sup> in labial technique, and Fillión<sup>5</sup> in lingual technique, among others, have contributed to the development of the interproximal reduction technique currently in use. Anthropologists have usually found little to no crowding in the remains of primitive dental arches. The theory that primitive humans wore down their teeth more rapidly is difficult to dispute. Foods were much more difficult to masticate, often contained abrasive particles

such as sand or bone, and primitive people used their teeth to cut and shred foods. This tooth wear resulted in uncrowded dental arches.

### The Need for Interproximal reduction

Modern research has found that as we age, normal mesial drift of the teeth causes crowding in many individuals regardless of whether or not orthodontic treatment was performed. Studies on the occlusions of Aborigines found that they presented with interproximal wear with loss of up to 14–15 mm of hard tissue over a lifetime as a consequence of non-refined diets, and had no crowding.<sup>6,7</sup> Sicher<sup>8</sup> stated that tooth wear (attrition) has a positive function and asked whether nature sacrifices tooth substance to achieve an increase in functional potentiality. Peck and Peck<sup>9</sup> found a relationship between dental size (mesiodistal and labiolingual distances of the inferior incisors) and crowding grade (PI index). Betteridge<sup>10</sup> also found a relationship between dental size and crowding grade. Teeth vary in size between females and males, mostly in the permanent dentition, with men having larger teeth and the maxillary centrals and canines showing the greatest differences.<sup>11–16</sup> Bolton<sup>17</sup> analyzed the relationships between canine-to-canine widths and molar-to-molar widths in dental arches, and found tooth size discrepancies in approximately 30% of patients. Freeman, Santoro and Alexander<sup>18</sup> also observed similar percentages in their studies. Sasouni<sup>19</sup> found that Class III facial types and patients with deficient maxillary growth show a greater incidence of anterior tooth shapes and agenesis. Cua-Benward<sup>20</sup> found similar results in Class III subjects, and tooth deformities in the lower anterior region in Class II individuals.

### Periodontal Considerations

It is apparent from the literature that there is no negative or positive effect when teeth approximate after interproximal reduction. Investigators studying horizontal and vertical bony defects on posterior teeth found no evidence that narrow spaces between roots were risk factors for periodontal disease. Other investigators found that teeth could function even when the roots were touching and sharing a periodontal ligament. After reviewing several studies, Fillión<sup>21</sup> concluded that periodontal state is improved even if interproximal reduction is performed on already aligned teeth and the interdental septum thickness is reduced as a result. Betteridge<sup>22</sup> found that fourteen of seventeen interproximal reduction cases had an improved gingival index. Boese<sup>23</sup> compared forty patients' radiographs taken four to nine

years post-treatment and found no significant differences in alveolar crest height. Crain<sup>24</sup> and Sheridan<sup>25</sup> found no significant differences in the gingival index interproximally three to five years post-treatment. Enamel reductions in the above studies were maximum 0.5 mm per proximal surface.

### Contact Locations

As cutting instruments remove enamel during interproximal reduction, rounded contours are flattened. These need to be restored after enamel reduction to restore the contact back to the proper location. Recontouring dental shape and anatomy is important: contact points are more apical as the teeth move from the anterior of the mouth to the posterior, and restoring them to their proper position should be attempted.

### Enamel Thickness

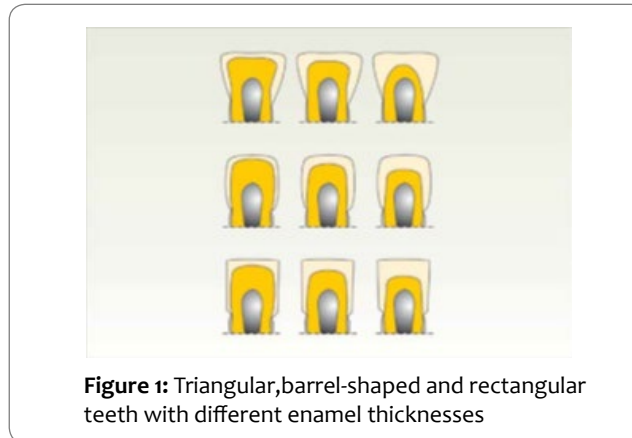
Studies have demonstrated that the enamel thickness around teeth is similar in incisors, cuspids, molars, and premolars. A study by Hall<sup>26</sup> et al. demonstrated that mandibular lateral incisors have thicker enamel than central incisors. Enamel thickness of the lower central incisor was determined: 0.77 mm +/- 0.11 mm on the distal and 0.72 mm +/- 0.10 mm on the mesial. The lower lateral incisor measured 0.96 mm +/- 0.14 mm on the distal and 0.80 mm +/- 0.11 mm on the mesial. Enamel thick-

ness in premolars can be well over 1 mm.

The minimal enamel thickness, and not the average values, must be taken into account when determining the enamel quantity that is going to be removed, since it is not possible to know which teeth present minimal thickness. There is no relationship between dental size and enamel thickness; therefore, macrodontic teeth should not be stripped more than microdontic teeth (although aesthetically it is better to carry out the slenderizing on macrodontic teeth). Enamel thickness is slightly greater in the contact point, gradually decreasing in thickness toward the cemento-enamel junction. The enamel is slightly thinner in distal than in mesial surfaces. In upper cuspids and lower second bicuspid, these differences are greater. The exceptions are upper lateral incisors, whose thickness is slightly greater distally.<sup>27,28,29</sup>

### Tooth shape and enamel thickness

According to Bennett and McLaughlin<sup>30</sup>, we can distinguish three main dental shapes: rectangular, triangular, and barrel shaped teeth. Studies reveal that there is no relationship between dental shape and enamel thickness (Fig. 1). Therefore, it is not possible to vary the amount of interproximal reduction depending on dental shape and the only element of decision should be the minimal enamel thickness. It is true, though, that more space is gained with minimal enamel wear in triangular-shaped teeth.



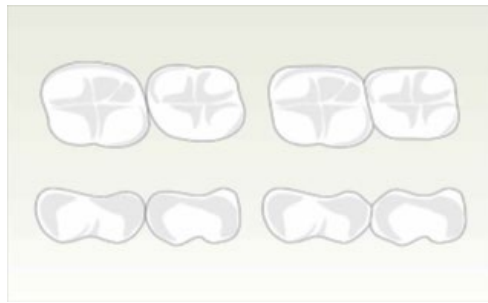**Figure 1:** Triangular, barrel-shaped and rectangular teeth with different enamel thicknesses

### How much enamel can be removed?

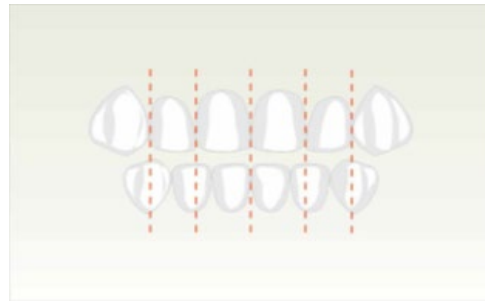
Generally, it is recommended to remove approximately half of the enamel thickness on any surface being reduced. As a rule of thumb, be very conservative; never remove more than 0.3 mm (including polishing) from any single tooth surface, creating space gain of 0.6 mm per contact. Several clinicians have provided their recommendations for interproximal reduction. Boese<sup>23</sup> recommends slenderizing half the enamel layer thickness. Berrer<sup>31</sup> claims that lower incisors can be stripped by 0.4 mm, which corresponds to a 0.5 mm slenderizing per proximal surface of the lower incisors. Paskow<sup>32</sup> allows slenderizing of between 0.25 mm and 0.37 mm. Hudson<sup>27</sup> suggests 0.20 mm for central incisors, 0.25 mm for the lateral ones, and 0.30 mm for the lower cuspids, which gives a total of 3 mm for the whole anterior group. Tuverson<sup>33</sup> states 0.3 mm per proximal surface of the lower incisors and 0.4 mm in cuspids, which gives, in total, the elimination of 4 mm in the anterior group. Alexander<sup>18</sup> permits only 0.25 mm for all the teeth, and Sheridan<sup>34</sup> defends a 0.8 mm slenderizing per each surface of posterior teeth and 0.25 mm in the anterior teeth, gaining in total some 8.9 mm. The concept of removing half the enamel layer would seem to be clinically acceptable. According to Fillión<sup>35</sup>, it is possible to

obtain 10.2 mm of space in the maxilla and 8.6 mm in the mandible if slenderizing is carried out from the mesial surface of the first right molar to the same surface of the left molar. If slenderizing includes the second molar, an additional 0.5 mm in distal surface of the first molar and 0.5 mm in mesial surface of the second molar can be obtained. When planning slenderizing, factors that must be considered include the degree of physiologic abrasion present (contact tips or facets) (Fig. 2), whether the patient has already undergone slenderizing, and the presence of over-dimensioned crowns or fillings.

When slenderizing incisors and cuspids, asymmetries should be compensated for and midlines centered (Fig. 3). In the case of bicuspid and molars, the cusps should remain intercuspidated (Fig. 4). The Bolton index is useful to determine the best zone for slenderizing. It should be carried out such that the vertex of the interdental papilla and the contact point remain in the same perpendicular line to the occlusal (vertical) plane (Fig. 5). Otherwise, the teeth will look as if they are incorrectly inclined. The interproximal contact point remains at a distance of 4.5–5 mm from the upper border of the bone crest. This ensures that “black gingival triangles” will not be visible due to the absence of the dental papilla. The bone crest height is determined by probing and radiographic examination (Fig. 6).



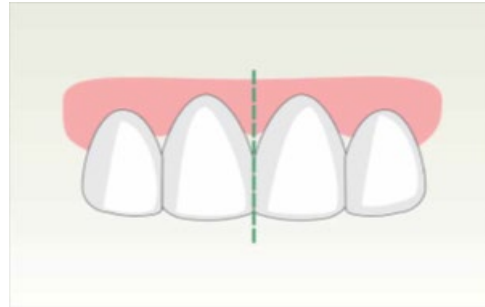
**Figure 2:** Normal evolution increases the contact area into a contact surface.



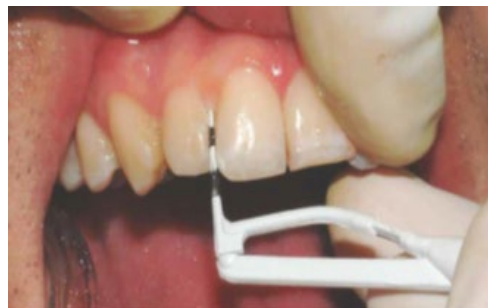**Figure 3:** Slenderizing from cuspid to cuspid must improve the midline and dental symmetry.



**Figure 4:** Slenderizing of the posterior teeth must improve the occlusion.



**Figure 5:** The vertex of the dental papilla and the contact point must be in the same vertical line.



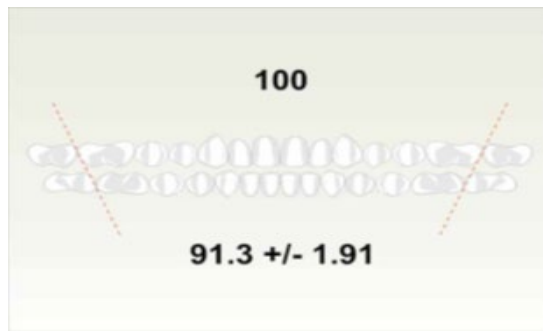
**Figure 6:** distance measured from the alveolar bone crest till the contact point.

### Indications for Interproximal reduction

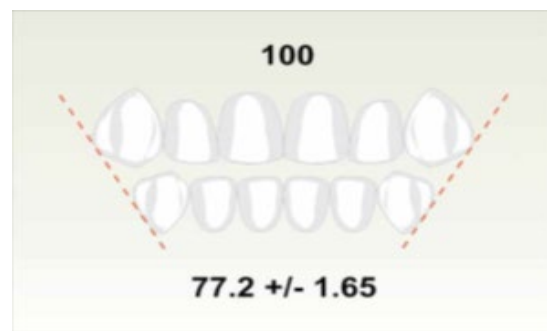
- Requires space in the dental arches without extractions.
- Where individual tooth sizes prevent a Class I molar and canine relationship.
- Bolton Discrepancy Cases

In an ideal dentition, Class I canines should create the proper space mesial to the canines to accommodate the lateral incisors and central incisors. Likewise, Class I molars should create enough space to

accommodate the first and second premolars, canines and incisors. Other factors include tooth position, overjet, and overbite. In many cases, patients present with tooth size discrepancy, described by the Cuspid-to-Cuspid Bolton Index (maxillary or mandibular – 6 teeth) or the first Molar-to-first-Molar Bolton Index (maxillary or mandibular – 12 teeth). Bolton determined that the relation between the upper and lower molar-to-molar tooth size is  $91.3 \pm 1.91$  (Fig. 7). The same cuspid-to-cuspid relation is  $77.2 \pm 1.65$  (Fig. 8).



**Figure7:** Molar-to-Molar Bolton Index (12 teeth)



**Figure8:** Cuspid-to-Cuspid Bolton Index (6 teeth).

If the “12 teeth” Bolton index is accomplished, the molar Class I relationship is obtained, and if the “6 teeth” Bolton index is accomplished, the Cuspid Class I relationship is obtained. If the patient presents with Bolton discrepancies, it is necessary to compensate for this discrepancy with interproximal reduction of the dental arch in order to achieve a good occlusion. If teeth are too small, space should be opened, and build-ups should be performed. For example:

- A “12 teeth” Bolton excess of the upper arch of 4 mm with a “6 teeth” Bolton excess of the upper arch of 4 mm indicates that interproximal reduction should occur in the upper cuspid-to-cuspid zone.
- A “12 teeth” Bolton excess of the upper arch of 4 mm with a normal “6” Bolton index indicates that interproximal reduction should occur in the upper molars and bicuspid zone.
- A “12 teeth” Bolton excess of the upper arch of 4 mm with a “6 teeth” Bolton excess of the upper arch of 2 mm indicates that interproximal reduction should occur in all the upper teeth. The same principles are used for lower arch Bolton excess.

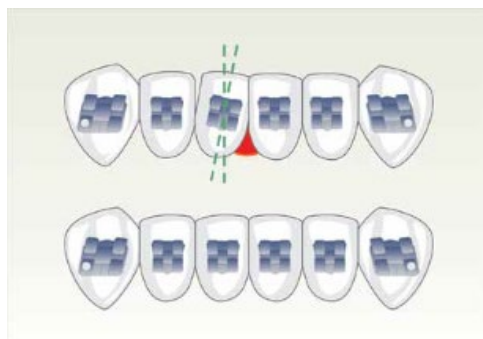
#### d) Tooth Shape and Interproximal reduction

A rectangular shape allows a wide and stable contact point, without visible spaces.

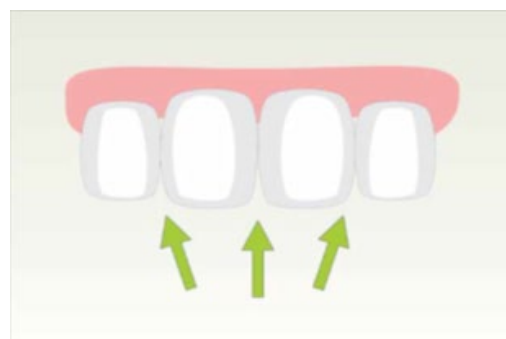
A triangular shape allows a reduced occlusal or incisal contact point. Patients presenting with triangular teeth may present with “black gingival triangles”.

Barrel-shaped teeth have reduced contact points in the middle with apparent separations at the incisal level. It is possible that gingival (triangular teeth) or incisal (barrel-shaped teeth) spaces may not be visible at the start of treatment due to crowding or rotations. It is important to inform patient of the potential for the creation of “black triangles” and to document it in the chart prior to treatment. Ideally, include the solution to this problem in the treatment plan regardless of whether fixed appliances or clear aligners will be used.

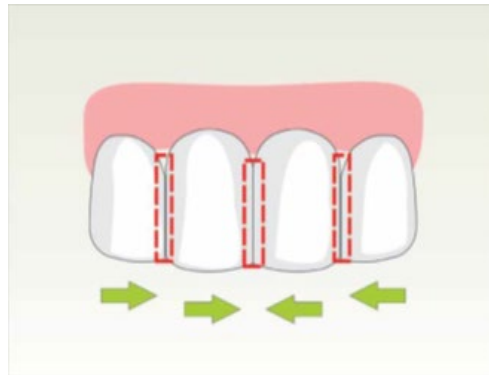
If the crown has a triangular shape, the distance between the bone crest and the contact point is relatively long. These cases show more tendencies to an absence of the interproximal papilla. Tarnow et al. demonstrated that if the distance from the contact point to the end of the interdental bone crest is 5 mm or less, the papilla is present in 100% of the cases. If this distance is 6 mm, the papilla is found in 56% of cases, and if it is 7 mm or more, the papilla is present only in 27% or less<sup>36</sup>. From the bone crest end to the papilla end, the distance is always 4.5 mm. “Black gingival triangles” are not always the result of an enlarged distance between the contact point and the bone crest. According to Bennett and McLaughlin<sup>37</sup>, a “black gingival triangle” can appear as a consequence of a bracket malpositioning with respect to inclination (**Fig. 9**). In this case the bracket position should be corrected and interproximal reduction should not be carried out. In barrel-shaped teeth it is possible to carry out interproximal reduction and recontouring, (**Fig.10, 11**).



**Figure9:** Black gingival triangle following bracket malpositioning



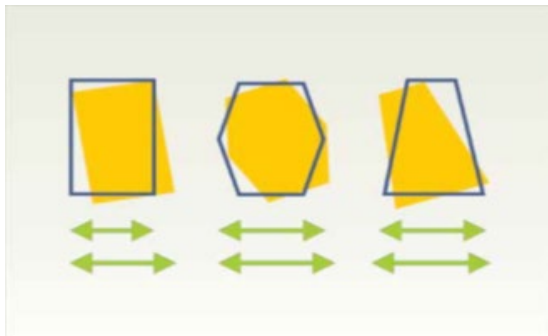
**Figure10:** Barrel-shaped teeth showing visible incisal spaces (according to Bennett and McLaughlin).



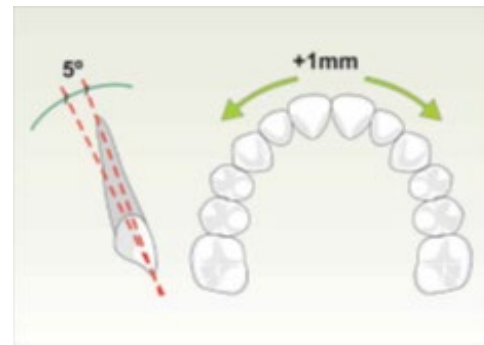
**Figure 11:** Slenderization and reapproximation performed to reduce incisal spaces.

Triangular and barrel-shaped teeth often require slenderizing or cosmetic restoration to improve the aesthetics after orthodontic treatment. This should be considered before finishing the case and debonding the brackets. Rectangular-shaped teeth do not show any “black triangles”, and interproximal reduction is usually not favorable as too much tooth reduction is required to gain sufficient space in the dental arch. According to Andrews, teeth that are tipped more

mesiodistally occupy more space in the dental arch than teeth in a more vertical position do. Bennett and McLaughlin emphasize that this fact is truest for rectangular teeth (**Fig. 12**). Thus, uprighting as a space gaining solution is possible only in rectangular teeth. Steiner states that for each millimeter of protrusion, the discrepancy is reduced by 2 mm. Torque enlargement without protrusion permits a gain of 1 mm per 5° of palatal root torque enlargement (**Fig. 13**)<sup>38</sup>.



**Figure 12:** Importance of the rectangular shape, which influences the space occupied by a tooth in the dental arch, in relation to its inclination.



**Figure 13:** Gain of 1 mm of space.

While tooth shape has no influence on enamel thickness, it is aesthetically more advisable to slenderize large (macrodontic) teeth rather than small (microdontic) teeth. The “Golden Proportion” described by Ricketts<sup>39</sup> between upper central incisors and lateral incisors can be taken into account, too. If crowns and fillings are overcontoured, these should be re-shaped to give the tooth its normal dimensions.

#### e) Bilateral Dental Asymmetries

Depending upon tooth size and available space, interproximal reduction or veneers and crowns are often indicated in order to compensate for dental asymmetries, especially in the upper anterior teeth.

#### f) Adult Patients

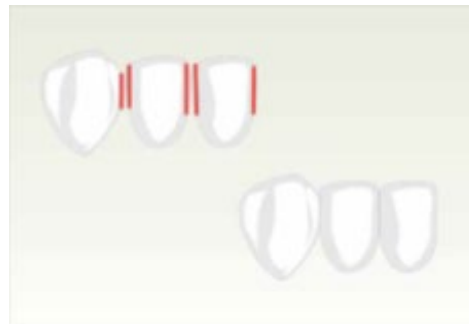Adults show more pulp retraction, and therefore slenderizing can be carried out with less risk of dentinal sensitivity than in young patients.

#### g) Patients with Low Caries Index

Interproximal reduction should be carried out only in patients with a low caries index and good oral hygiene, to avoid increased caries susceptibility.

#### h) Multiple Tooth Rotations

In patients with multiple rotations, interproximal reduction can provide wider interproximal contact facets that make relapse less likely (**Fig. 14**). Many orthodontists purposely flatten out contacts in the lower anterior region in the belief that relapse can be prevented or minimized due to the proximation of the flat contacts.



**Figure 14:** With slenderization, contact points can be brought closer to the interdental septum crest.

### Contraindications for Interproximal reduction

- should generally be avoided on small teeth ;
- restored with a normal shape;
- have enamel hypoplasia;
- are severely rotated whereby the proper contact area is not accessible. In such cases, it is recommended to either make space with separators or wait until crowding in the area is resolved.
- patients who do not accept interproximal reduction as a treatment option (informed consent is imperative);
- patients with a high caries index, poor oral hygiene;
- rectangular-shaped teeth; and
- young patients with large pulp chambers.

### Advantages of Interproximal reduction

Interproximal reduction minimizes potential consequences created by extraction, which can include:

- Difficulties in complete space closure and in paralleling the roots next to extraction sites
  - Need for greater anchorage reinforcement than in interproximal reduction cases (anchorage is still fundamental in the interproximal reduction technique)
  - Possibility of the space re-opening (relapse), especially in adult patients
  - Unwanted profile changes related to retroclining incisors when closing extraction spaces.
- dental movements are smaller than in extraction cases and treatment is shorter.
- The risk of root resorption is also reduced.
  - Interproximal reduction allows “black gingival triangles” to be avoided or reduced,
  - dental asymmetries to be compensated for and, when needed, dental shape to be improved.

### Disadvantages of Interproximal reduction

- Techniques that are not conservative, together with operator error, can result in enamel damage or over-reduction (which can require subsequent orthodontic closure).
- Tooth contours can easily be destroyed, after which a restorative procedure is required.
- Use of instruments which lack control is not recommended.
- High-speed diamond disks easily slice teeth, taking their own path are not recommended.

### Slenderizing Goals

- The most important goal when performing interproximal reduction is to do no harm!
- Remove enamel only on teeth that can tolerate interproximal reduction.
- Take care to replace the contact point between teeth in the correct anatomical location after interproximal reduction,
- To restore tooth contours to the original form as much as possible and
- To polish the enamel using finishing disks or strips.

### Instruments Used to Slenderize


#### Stainless Steel Strips

Abrasive strips are available with single- or double-sided coatings, and in fine, medium, and coarse grits. Strips are useful when the teeth are so rotated that a disk is not appropriate. In addition, thin, fine strips allow you to pass through any contact, regardless of rotation or angulation of the teeth. After a strip is passed through the contact, access with a diamond disk is easier, more predictable, and more effective. Strips are also useful for re-contouring teeth that have been reduced. In addition, patients are less apprehensive if performed for the first time manually with a strip, rather than with a motorized handpiece. Strip holders aid manual interproximal reduction. Some manufacturers offer strips that can be hand-held or inserted in a contra-angle handpiece that performs a reciprocating motion of 1.6mm to achieve reduction (DENTSPLY SpaceFile® or IDEAL® Strips).

#### Diamond Disks (High Torque)

Diamond disks are available in varying thicknesses and grits (fine, medium and coarse), similar to strips. Using the thinnest disk available (~0.17 mm) allows for 0.2 mm of interproximal reduction after polishing. Single- and double-sided disks are available. Using only single-sided disks keeps the initial contact break as small as possible, and ensures that only one tooth is being cut a time. A fine grit disk is usually sufficient.

Up and down disks enable use of disks with coatings on opposite sides during interproximal reduction - the up and the down refers to the side on which the disk is coated with diamonds. Disks are also available with a mesh configuration for fine contouring (Fig. 15). If using a high torque system, be certain to use high-torque disks manufactured for use at low speeds delivered with a high torque motor.



**Figure 15:** High-torque diamond and mesh disks

### Air Rotor Interproximal reduction Burs and Disks

Air rotor interproximal reduction (air-powered high-speed motors at up to 200,000 rpm, and slow-speed motors that rotate at 20,000 rpm or 5,000 rpm) lacks control and less conservative. It is difficult to control degree of cutting power even when slowing down the turbine. Achieving a controlled speed using the foot rheostat is difficult, as the air running through the motor can compress and alter the speed regardless of where the pedal is. At these speeds, the diamond disk can easily bind when breaking contact, resulting in soft- and hard-tissue damage; the diamond-coated disk can also take a path other than the one the dentist desires, cutting into dentin.

### Electric Rotor Interproximal reduction Burs and Disks

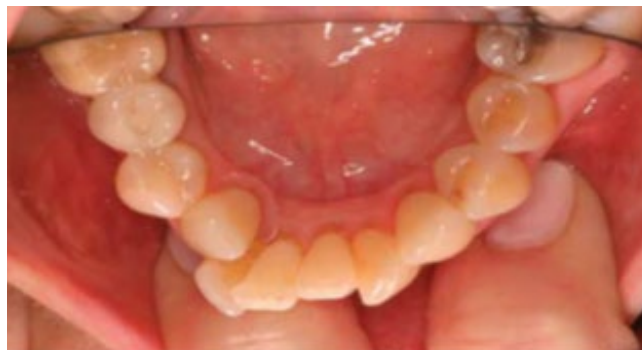Electric handpieces can reach the same speeds as air turbines while allowing you to reduce bur or disk to revolutions as low as 100 rpm. With low speeds and high torque cutting power, safety and accuracy

are now achievable. Most electric motors cannot deliver the torque needed to safely cut enamel and the rotating disk will stop (similar to air turbines). Unlike disks in air turbines at high speed, if the diamond disk is slightly bent it can still be used at low speed and does not need to be immediately replaced.

### Slenderizing Technique

#### Interproximal reduction Chart

It is important to first review the written treatment plan and document all interproximal reductions you perform. A diagram similar to a periodontal chart is recommended and interproximal reduction measurements can be written between the teeth on the chart. Determine the sequence of interproximal reduction based on rotations and access to contact points (**Figure 16**). This lets you move the teeth into the newly created space, opening up the contacts between the teeth where there was previously no access.



**Figure 16:** Dental arch with numbered sequence for Slenderization

### Separating Teeth

Use of a wedge to open up contacts prior to interproximal reduction can be painful for patients and need time for separators to work; additionally, it is difficult to measure the space being created by interproximal reduction due to the space created by the separators. You may see 3 mm of space, when in fact 2.5 mm of this space was made by the separator and will relapse by the next visit.

### Thickness Gauges/Leaf Gauges

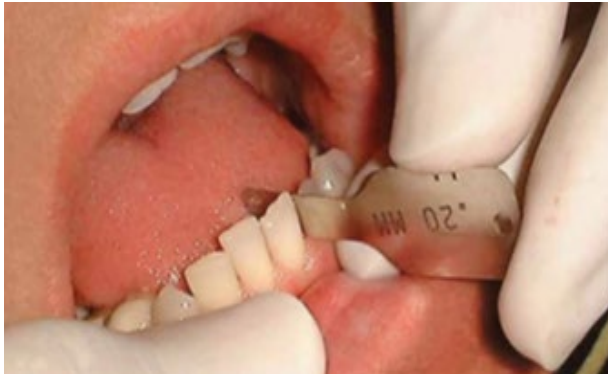Make the initial measurement using a leaf gauge (**Fig. 17**).

Leaf/thickness gauges are readily available and provide an accurate and simple way to measure interproximal reductions. Using the thickness of a diamond disk or width of a diamond bur to measure interproximal

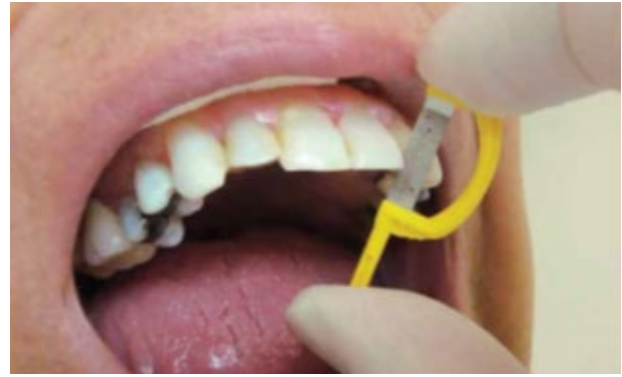reduction performed is pointless; even if only passed between the contacts once, the amount of interproximal reduction will most likely be larger than the width of the cutting instrument. In the case where a contact is already opened, simple mathematics should be performed to determine space gained by interproximal reduction.

The space made will be approximately 0.2 mm, due to the width of the disk that has already been used. If 0.5 mm total interproximal reduction is required and only half of this will be done at the first visit, there is no need for final polishing. This will be accomplished at the last visit, when the remaining 0.2 mm of interproximal reduction occurs.

For every contact that is to be slenderized, first open the contact manually with a contact point saw or a single-sided diamond-coated strip (**Fig. 18**).



**Figure 17:** measuring with a leaf gauge



**Figure 18:** Use of SpaceFile® Strips

Next, use a new single-sided file or disk (up or down depending on which tooth is being slenderized) to increase the thickness of the space made using the diamond strip. Using an ERS slow-speed handpiece at low speed and high torque diamond disks is effective. Clear disk guards are available that fit over diamond disks leaving the cut-

ting area exposed while protecting the adjacent tooth that is not being slenderized. These clear disk guards can be used manually with the finger rests or over the handpiece (**Fig. 19**). When completely satisfied with the amount of space created, contour the contacts and polish the surfaces. A diamond or carbide polishing bur can be used with 500 rpm.



**Figure 19:** Clear disk guard

## Conclusion

Do not create too much space. Perform slenderizing procedures slowly, removing only minimal amounts of enamel needed for the tooth movement. Using a single-sided diamond-coated disk with a high-torque electric motor enables the disk to easily move through the contact for interproximal reduction that is accurate, and safe for the adjacent tooth. Clear disk guards can also be used.

## References

- Rossouw PE, Tortorella A. [Enamel reduction procedures in orthodontic treatment](#). J Can Dent Assoc. 2003; 69(6):378-83
- Black GV. Descriptive anatomy of the human teeth. 4th ed Philadelphia: SS White Dental, 1902.
- Ballard R, Sheridan JJ. [Air-rotor stripping with the Essix anterior anchor](#). J Clin Orthod. 1996; 30:371-373.
- Sheridan JJ. [Air-rotor stripping](#). J Clin Orthod. 1985;19:43- 59.
- Fillion D. Apport de la sculpture amélaire interproximale à l'ortodontie de l'adulte (troisième partie). Rev Orthop Dento Faciale. 1993;27:353-367.
- Begg PR. Begg orthodontic theory and technique. Philadelphia: WB Saunders, 1965: 74.
- Murphy T. [Reduction of the dental arch by approximal attrition](#). Br Dent J. 1964;116: 483-488.
- Sicher H. [The biology of attrition](#). Oral Surg. 1953;6:406-412.
- Peck H, Peck S. [An index for assessing tooth shape deviations as applied to the mandibular incisors](#). Am J Orthod. 1972; 61:384-401.
- Betteridge MA. [Index for measurement for lower labial segment crowding](#). Br J Orthod. 1976;3:113-116.
- Garn SM, Lewis AB, Kerewsky RS. [Sex difference in tooth size](#). J Dent Res. 1964; 43:306-307.
- Beresford JS. [Tooth size and class distinction](#). Dent Pract. 1969;20:113-120.
- Sanin C, Savara BS. [An analysis of permanent mesiodistal crown size](#). Am J Orthod. 1971; 59:488-500.
- Potter RH. [Univariate versus multivariate differences in tooth size according to sex](#). J Dent Res. 1972;51:716-722.
- Arya BS, Savara BS, Thomas D, et al. [Relation of sex and occlusion to mesiodistal tooth size](#). Am J Orthod 1974;66:479-486.
- Doris JM, Bernard BW, Kuftinec MM, Stom D. [A biometric study of tooth size and dental crowding](#). Am J Orthod.1981; 79:326-336.



17. Bolton WA. Disharmony in tooth size and its relation to the analysis and treatment of malocclusion. *Angle Orthod.* 1958; 28:113–130.
18. Alexander RG. *The Alexander discipline contemporary concepts and philosophies*. Angel GA, ed., 1986.
19. Sassouni V. A classification of skeletal facial types. *Am J Orthod.* 1969; 55:109–123.
20. Cua-Benward GB, Dibaj S, Ghassemi B. The prevalence of congenitally missing teeth in class I, II, III malocclusions. *J Clin Pediatr Dent.* 1992;17:15–17.
21. Fillion D. Apport de la sculpture amélaire interproximale à l'orthodontie de l'adulte (deuxième partie). *Rev. Orthop Dento Faciale.* 1993;27:189–214.
22. Betteridge MA. A method of treatment for incisor crowding. *Br J Orthod.* 1979;6:43–48.
23. Boese LR. Fiberotomy and reproximation without lower retention, nine years in retrospect. *Angle Orthod.* Part I. 1980;50:88–97. Part II. 1980;50:169–178.
24. Crain G, Sheridan JJ. Susceptibility to caries and periodontal disease after posterior air-rotor stripping. *J Clin Orthod.* 1990;24:84–85.
25. Sheridan JJ. Air-rotor stripping update. *J Clin Orthod.* 1987;21: 781–788.
26. Hall NE, Lindauer SJ, Tufekci E, et al. General Session and Exhibition, Brisbane, 2006.
27. Hudson AR. A study to the effects of mesiodistal reduction of mandibular anterior teeth. *Am J Orthod.* 1956;42:615–624.
28. Gillings B, Buonocore, M. An investigation of enamel thickness in human lower incisor teeth. *J Dent Res.* 1961;40:105–118.
29. Shillingburg HT, Grace CS. Thickness of enamel and dentin. *J S Calif St Dent Assoc.* 1973;41:33–52.
30. Bennett JC, McLaughlin RP. Consideraciones sobre la forma de la corona de los incisivos en el tratamiento ortodóncico. *Rev Esp Ortod.* 1997;27:359–369.
31. Berrer HG. Protecting the integrity of mandibular incisor position through keystone procedure and spring retainer appliance. *J Clin Orthod.* 1975; 9:486–494.
32. Paskow H. Self-alignment following interproximal stripping. *Am J Orthod.* 1970; 58:240–249.
33. Tuverson DL. Anterior interocclusal relations: Part I. *Am J Orthod.* 1980; 75:361–370.
34. Sheridan JJ, Ledoux PM. Air-rotor stripping and proximal sealants: An S.E.M. evaluation. *J Clin Orthod.* 1989; 23:790–794.
35. Fillion D. Apport de la sculpture amélaire interproximale à l'orthodontie de l'adulte (troisième partie). *Rev. Orthop Dento Faciale.* 1993;27:353–367.
36. Tarnow DP, Magner AW, Fletcher P. The effect of the distance from the contact point to the crest of bone on the presence or absence of the interproximal dental papilla. *J Periodontol.* 1992;63(12):995-6.
37. Bennett JC, McLaughlin RP. Consideraciones sobre la forma de la corona de los incisivos en el tratamiento ortodóncico. *Rev Esp Ortod.* 1997; 27:359–369.
38. Bennett JC, McLaughlin RP. Manejo ortodóncico de la dentición con el aparato preajustado. *Isis Medical Media*, 1998.
39. Ricketts R M. In Brodie A.G.: *The three arcs of mandibular movement as they affect the wear of teeth*. 1969; 39:217–229.