



Cardiac Tamponade: A Case Series

Chiu-Yang Lee^{*1,2}

¹Division of Cardiovascular Surgery, Department of Surgery, Taipei Veterans General Hospital, China

²Department of Senior Citizen Service Management, Chia Nan University of Pharmacy and Science, Taiwan, R.O.C, China

Abstract

Cardiac tamponade is a condition in which the heart is compressed by excess fluid in the pericardial space, which can result in diastolic filling impairment, subsequent cardiac dysfunction, and even cardiac collapse. Cardiac tamponade is an uncommon sequela of chest contusions from blunt chest trauma that brings with it a severe risk of sudden death. We present a small series of cases with successful treatment for cardiac injuries: a young man who was struck by a bull cart and an old man with chronic kidney disease receiving stent graft placement for superior vena cava syndrome. This report highlights the need to remain alert for cases of tamponade, and measures such as emergent pericardiocentesis should first be administered to maintain the hemodynamics of vital organs such as the heart.

Keywords: Kothimbda, Packaging material, Ascorbic Acid, etc

Corresponding author: Chiu-Yang Lee

Division of Cardiovascular Surgery, Department of Surgery, Taipei Veterans General Hospital, China. Tel: +886-2-2875-7495,

E-mail: davidlee0501@gmail.com

Citation: Chiu-Yang Lee (2018), Cardiac Tamponade: A Case Series. Int J Car & Hear Heal. 2:3, 13-15

Copyright: ©2018 Chiu-Yang Lee. This is an open-access article distributed under the terms of the Creative Commons Attribution License, which permits unrestricted use, distribution, and reproduction in any medium, provided the original author and source are credited

Received: July 03, 2018

Accepted: July 13, 2018

Published: September 25, 2018

Introduction

Cardiac tamponade is a condition in which the heart is compressed by excess fluid in the pericardial space, which can result in impaired cardiac filling, subsequent cardiac dysfunction, and even cardiac collapse. Cardiac tamponade is an uncommon and fatal sequela of chest contusions from blunt chest trauma that can frequently lead to death if left undiagnosed. Common causes of cardiac tamponade vary, but they include acute pericarditis, postmyocardial infarction, cardiac surgery, sharp or blunt chest trauma, aortic dissection, and malignancy.

Pericardial effusions may develop rapidly (acute) or more gradually (subacute or chronic). When intrapericardial pressure develops quickly and becomes high enough to impede cardiac filling, cardiac function quickly becomes impaired, and cardiac tamponade can be considered

present and acute.

The true incidence of cardiac rupture following blunt chest contusion is not well documented, with current records primarily dependent on geography and patient population. Herein, we present successful treatment for cardiac tamponade following cardiac injuries in a young man who was struck by a bull cart and an old man with chronic kidney disease receiving stent graft placement for superior vena cava syndrome. This report highlights the need to remain alert for cases of tamponade, and life-saving measures such as emergent pericardiocentesis should first be administered to maintain the hemodynamics of vital organs such as the heart.

Case 1

An 18-year-old man was involved in a high-speed frontal collision in which his motorcycle struck a bull cart. Approximately 30 minutes later, he was admitted to the emergency room. At presentation, he was confused, violent, and complaining of thoracic and abdominal pain. He developed hypotension with a systolic blood pressure ranging between 60 and 80 mmHg, with a pulse rate of 120 bpm and a respiratory rate of 35 breaths per minute. Bruise marks were found on his right flank as well as on his chest. His extremities were clammy with marked peripheral hypoperfusion. Notably, his external jugular veins were distended. Cardiovascular examination revealed auscultated and muffled dual heart sounds with no cardiac murmur. Plain X-ray suggested a widened mediastinum. After chest and abdominal computed tomography (CT) scans were finished, he underwent circulatory collapse. The CT scans revealed massive pericardial effusion and confirmed cardiac tamponade. After emergency pericardiocentesis with echocardiography, the patient was quickly transferred to the operating room, undergoing a median sternotomy incision. After cardioplegic arrest under assistance of a heart-lung machine, a 1.5-cm tear was found at the junction of the right atrium and superior vena cava (Fig. 1) The tear was repaired with Teflon-butressed sutures. The patient's postoperative course was uneventful, and he was discharged on postoperative day 15.

Citation: Chiu-Yang Lee (2018), Cardiac Tamponade: A Case Series. Int J Car & Hear Heal. 2:3, 13-15.

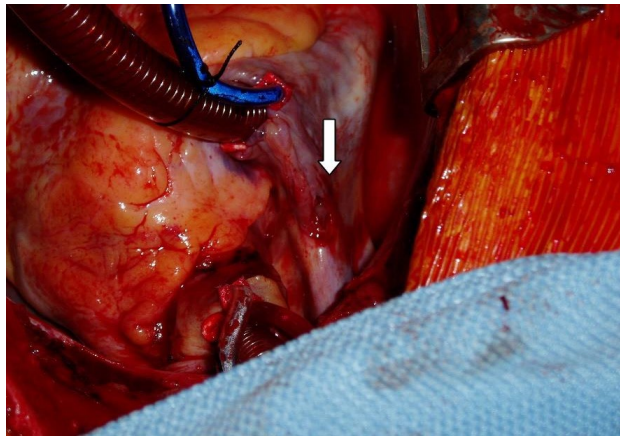


Fig 1: A 1.5-cm tear was found at the junction of the right atrium and superior vena cava (see arrow).

Case 2: A 78-year-old man with a history of diabetes mellitus, cerebrovascular accident, superior vena cava syndrome, and chronic kidney disease with regular hemodialysis underwent placement of gore extension limb stents to treat his obstruction of right brachiocephalic vein (Fig. 2).

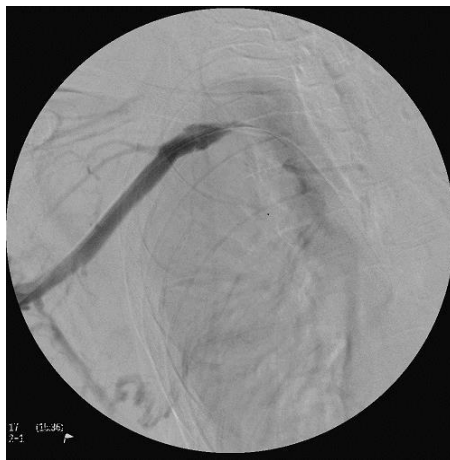

figure A

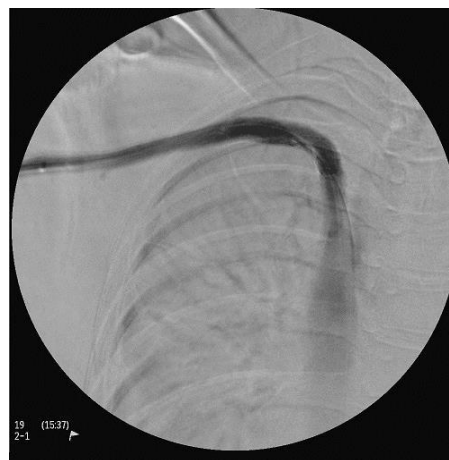

figure B

Fig 2: (A) Obstruction of right brachiocephalic vein. (B) Placement of gore extension limb stents from the proximal subclavian vein to the proximal superior vena cava.

After the procedure, he presented with newly onset dyspnea and clinical signs of hypotension. An emergency two-dimensional echocardiogram confirmed a diagnosis of cardiac tamponade. Therapeutic pericardiocentesis resulted in prompt cardiac relief, and his hemodynamics developed stably with a systolic blood pressure up to 90 mmHg. Later, the patient was transferred to the intensive care unit for observation. Simultaneously, bleeding tendency including prolonged activated partial thromboplastin time (aPTT) and activated clotting time (ACT) were corrected through transfusion of plasmapheresis and fresh frozen plasma. The patient's postoperative course was uneventful and he was discharged on day 8.

Conclusion

Incidence of myocardial rupture has decreased with the prevalence of urgent revascularization and aggressive pharmacological therapy for the treatment of acute myocardial infarction. The real occurrence of cardiac rupture following blunt chest trauma is not well documented, but reports have indicated that it occurs in less than 1% of patients with such trauma.¹ The mortality rate varies, ranging from 75% to 81.3% because of asymptomatic presentation, delayed occurrence, and delayed diagnosis.^{2,3}

Diagnosis of cardiac tamponade is challenging. The three principal features of tamponade (Beck's triad) are soft or absent heart sounds, hypotension, and jugular venous distension with a prominent "x"

descent but absent “y” descent.⁴ Because cardiac tamponade occurs only after myocardial injuries, prompt diagnosis with echocardiography and emergent pericardiocentesis should be undertaken to save patients’ lives.

In Case 1, the young man experienced a high-speed frontal collision with a bull cart, which is an unusual but nonetheless traumatic circumstance. Indeed, approximately 80%–90% of patients with cardiac rupture die almost immediately at the scene or before hospital admission.⁵ Reports have stated that the right ventricle is the chamber most frequently ruptured, followed by the right atrium and left ventricle.^{6,7}

In cases of cardiac injuries, previous history of heart disease and blunt mechanical forces must be considered.⁸ Mechanical forces associated with blunt chest trauma include deceleration, acceleration, compression, and shearing. Cardiac injuries caused by blunt chest trauma are more difficult to detect than penetrating injuries are, because the extent of damage caused by blunt trauma is less obvious, making actual diagnosis difficult. Therefore, patients with blunt chest trauma must be observed closely to detect any injuries that may not be initially apparent. In patients with blunt trauma and presenting with hemodynamic change, the diagnosis of cardiac rupture requires a high degree of clinical suspicion. Additionally, echocardiography is a useful tool for rapid detection of blood volume in the pericardial space before any signs of cardiac tamponade develop. However, if the patient is hemodynamically unstable, emergent pericardiocentesis should be performed immediately.

In most patients, immediate surgery is necessary and should not be delayed by attempts to stabilize the patient. The success rate in managing cardiac rupture depends on early recognition of its severity through careful observation and timely diagnosis. Although atrial tears have been managed without cardiopulmonary bypass (CPB), instituting CPB during surgery is effective and vital for such life-threatening situations. CPB can stabilize the hemodynamic state and allow surgeons to easily locate the site of bleeding after opening the pericardium, facilitating secure repair under an empty and relaxed

ventricular condition.⁹ In our cases, after removal of clots, bright red blood emanating from the right side of the pericardium was noted.

In summary, suspicion of blunt cardiac rupture, timely diagnosis, and proper management create an environment for life-saving treatment and effectively reduce subsequent mortality in patients with devastating cardiac injuries.

Acknowledgement

This manuscript was edited by Wallace Academic Editing.

Reference

1. Martin TD, Flynn TC, Rowlands BJ, Ward RE, Fischer RP. : [Blunt cardiac rupture. J Trauma 1984; 24:287-290.](#)
2. Fulda G, Brathwaite CE, Rodriguez A, Turney SZ, Dunham CM, Cowley RA: [Blunt Traumatic Rupture of the Heart and Pericardium. A ten-year Experience. J Trauma 1991; 31: 167-173.](#)
3. Brathwait CE, Rodriguez A, Turney SZ, Dunham CM, Cowley R: [Blunt Traumatic Cardiac Rupture – A Year Experience. Ann Surg 1990; 212 : 701-4.](#)
4. Harrison’s principles of internal medicine; 17 Ed Vol. 11-2008.
5. Got C. Mécanismes lésionnels des traumatismes thoraciques. In: Actualités en réanimation et urgences. SRLF Ed. Paris: Elsevier: 2000. p. 313-28.
6. Türk EE, Tsokos M. [Blunt cardiac trauma caused by fatal falls from height: an autopsy-based assessment of the injury pattern. J Trauma 2004; 57\(2\): 301-304.](#)
7. Diderys H, Strange PS. Rupture of the heart secondary to blunt trauma. *J Thorac Cardiovasc Surg* 1971; 62: 84-86.
8. Utter GH, Scherer LA, Wisner DH. [Blunt cardiac rupture in a patient with prior ventricular septal defect repair: a case report. J Trauma 2004; 57\(3\): 635-637.](#)
9. Yaku H, Fermanis G, Horton DA, Guy D, Lvoff R. Successful repair of a ruptured postinfarct pseudoaneurysm of the left ventricle *Ann Thorac Surg* 1995;60:1097-1098.