



Secondary Cryptogenic Brain Abscess with Cerebral Hernia During Absorption Stage of Cerebral Hemorrhage: Case Report and Literature Review

Peng Zou¹, Zhenhui Gao^{2*}, Wensheng Ren², Jian Liu¹

¹Department of Neurosurgery, Xijing Hospital Affiliated to the Air Force Military Medical University, Shaanxi, China

²Department of Neurosurgery, Jintai Hospital, Baoji city, Shaanxi, China

Abstract

Introduction: Brain abscess is a known complication of surgically treated intracerebral hemorrhage (ICH), but it is exceptionally rare that it occurs at the same site of a nonoperated ICH. This paper will report this special case, and present a literature review.

Patient concerns: A 62-year-old man with cerebral hemorrhage (about 25ml) in the right temporal occipital lobe was clearly conscious and initially treated conservatively.

Interventions: After 36 days of conservative treatment, the state of consciousness became worse, and imaging showed brain abscess with cerebral hernia at the same site of a nonoperated ICH. An emergency craniocerebral abscess resection was performed.

Outcomes: Postoperative pathology confirmed acute suppurative inflammation and necrosis, after symptomatic treatment successfully discharged.

Conclusion: There should be a high index of suspicion for a brain abscess following an intracerebral hemorrhage if the clinical and radiological picture differs from the expected course of a resolving hematoma.

Abbreviations: ICH=intracerebral hemorrhage, GCS=glasgow coma scale, CSF= cerebrospinal fluid, BBB=blood-brain barrier

Keywords: Brain abscess, Cerebral hemorrhage

Corresponding author: Zhenhui Gao

Department of Neurosurgery, Jintai Hospital, 8 Renmin Road, Baoji City, Shaanxi, 721000, China. Tel: +88009638748839,

E-mail: 1246569208@qq.com

Citation: Peng Zou et al. (2020), Secondary Cryptogenic Brain Abscess with Cerebral Hernia During Absorption Stage of Cerebral Hemorrhage: Case Report and Literature Review. *Int J Clinical & Case*. 4:1, 08-11

Copyright: ©2020 Zhenhui Gao et al. This is an open access article distributed under the terms of the Creative Commons Attribution License, which permits unrestricted use, distribution, and reproduction in any medium, provided the original author and source are credited

Received: January 31, 2020

Accepted: February 08, 2020

Published: February 24, 2020

Introduction

Brain abscess is a rare but potentially lethal infection of brain parenchyma, requiring prompt surgical intervention and high-dose antibiotic therapy, and it is estimated to affect 1/10,000 patients in developed countries^[1]. The incidence of brain abscesses is about 8% of intracranial masses in developing countries, whereas in the West the incidence is about 1-2%^[2]. Common sources of brain abscess include hematogenous spread from distant foci (pneumonia, infectious endocarditis) or contiguous sites (sinusitis, otitis, dental infection, cranial trauma)^[3]. Brain abscess is a known complication of surgically treated intracerebral hemorrhage (ICH), but it is exceptionally rare that it occurs at the same site of a nonoperated ICH^[4]. To the best of our knowledge, only 13 cases have been reported worldwide in the literature. Herein, we report a case of 62-year-old man presenting with a brain abscess 36 days after a nonoperated ICH. The patient underwent craniocerebral abscess resection and the postoperative pathology confirmed the brain abscess. This research was approved by the Ethics Committee of Xijing Hospital Affiliated to Air Force Military Medical University, and informed written consent was obtained from the patient for the publication of this case report and accompanying images.

Case report

A 62-year-old male with a previous history of hypertension about 5 years, with a maximum blood pressure of 180mmHg, took medication irregularly and had no other special history. The patient complained of sudden headache, nausea and vomiting for 3 days. The headache was an irregular attack, relieved after rest, accompanied by nausea, vomiting once, no other special discomfort symptoms. Physical

examination after admission: T36.4°C, P70 bpm, R20 bpm, BP 180/100mmHg. Consciousness was clear, Physical examination of heart, lung and abdomen was negative. The Glasgow coma scale (GCS) score was 14 and pupils were equal and reacting. There was Grade 4/5 power in the left upper and lower limbs. CT examination of the head on the first day after admission indicated cerebral hemorrhage (about 25ml)

in the right temporal occipital lobe (Fig. 1①). Admission diagnosis: hypertensive intracerebral hemorrhage. The patient was given temporary conservative treatment. CT scan of the head was performed on the 4th and 13th day after admission respectively (Fig. 1② and ③), indicating that the amount of hemorrhage was gradually reduced and the patient's mental state was gradually improved, but the headache was not relieved.

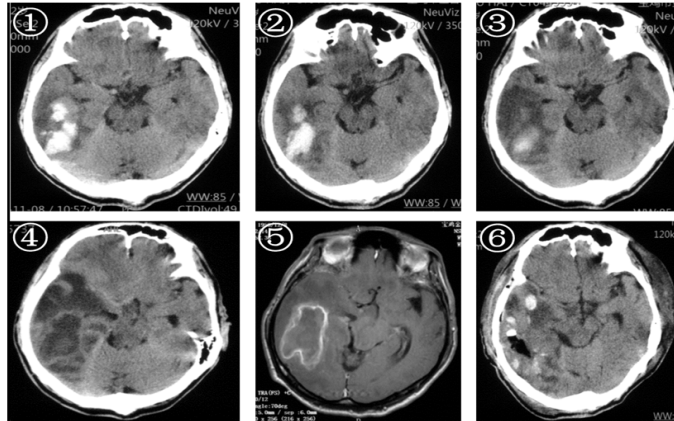


Figure 1: ①The CT scan on the 1st day of admission, showing high-density shadow of the right temporal occipital lobe, considering cerebral hemorrhage; ②The CT scan on the 4th day of admission showed that the hematoma volume decreased slightly; ③The CT scan on the 13th day of admission showed that the hematoma was mostly absorbed, with edema around; ④The CT scan on the 36th day of admission showed increased edema, slightly deviated midline, and cerebral herniation; ⑤The contrast-enhanced MRI scan on the 36th day of admission showed a typical ring enhancement at the site of the original hemorrhage; ⑥On the first day after the operation, the head CT scan showed that the lesion disappeared, the midline structure returned to normal.

On the 36th day after admission, the patient had a severe headache, accompanied by confusion of consciousness. The GCS score was 9 and pupils were equal and reacting. The patient was unable to cooperate with the examination of limb strength. The white blood cell count was $12.07 \times 10^9 / L$ (89.9% neutrophils). CT of the head showed increased edema, slightly deviated midline, and cerebral herniation (Fig. 1④). At this time, pulmonary CT reexamination showed no obvious inflammation. A cerebrospinal fluid (CSF) examination revealed an initial pressure of 330mmH₂O, a leukocyte count of $226 \times 10^6 / L$, a CSF glucose concentration of 2.73mmol/L, and a peripheral glucose level of 7.28mmol/L. CSF protein content was 155.4mg/dl. According to the expert consensus on the diagnosis and treatment of severe

neurosurgical patients in China in 2017, brain abscess was considered. Contrast-enhanced MRI showed a typical ring enhancement at the site of the original hemorrhage (Fig. 1⑤). Then the craniocerebral abscess resection was performed. *Staphylococcus aureus* growth was observed in pus culture. The drug sensitivity test is sensitive to vancomycin. Histopathologic examination of the excised brain abscess revealed acute suppurative inflammation with necrosis (Fig. 2). Vancomycin was injected intravenously after surgery. On the first day after the operation, the head CT examination showed that the lesion disappeared, the midline structure returned to normal and the state of consciousness improved (Fig. 1⑥). After 1 week, the limb activity was better than before, and 2 weeks after the operation, the patient was discharged from hospital.

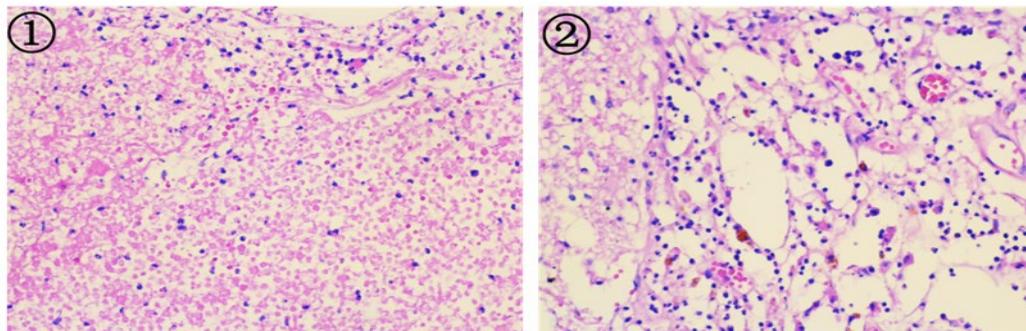


Figure 2: This suggested acute suppurative inflammation with necrosis. ①A large number of inflammatory cells were seen under the light microscope (HE, $\times 40$); ②Local vascular congestion, dilatation, fibrinous inflammation (HE, $\times 100$)

Discussion

Although brain abscess is an uncommon condition, it is life threatening, with a mortality rate of 0-10%, and requires early treatment. Mortality rates have reduced with the advent of CT and effective antibiotics^[5]. About 30% of the patients who survive can be left with neurological deficits and symptomatic seizures^[6]. A brain abscess developing at the site of a preceding intracerebral haemorrhage is rare, and to the best of our knowledge, only 13 such patients have been reported worldwide in the literature.

The case we report has two main characteristics: 1. The site of brain abscess occurs in the same site of absorption stage after cerebral hemorrhage. 2. Cryptogenic brain abscess. It refers to a type of brain

abscess whose etiology is not clear and whose infection source cannot be determined clinically^[7]. Through Pubmed and Chinese database retrieval, a total of 13 articles, 9 English literatures and 4 Chinese literatures are retrieved. These cases are summarized in Table 1. Among these cases, there are 9 males and 4 females, with an average age of 47.69±1.83 years. The average time from intracerebral hemorrhage to brain abscess formation is 40.31±2.57 days, however, the abscess formation time in our case was 36 days. There are 8 cases of unexplained brain abscess, 3 cases of pneumonia, 1 case of ductal associated bacteremia, and 1 case of vasculitis. 6 cases are staphylococcus aureus, 4 cases are negative, 2 cases are escherichia coli and 1 case is enterococcus. The case we reported is basically consistent with that reported in the literature.

Ref.	first authors	year	age/sex	intracranial part	Time to abscess formation afterICH(days)	primary site	pathogen
1	Ma Tian	2018	41/F	left occipital	6	no	Staphylococcus
2	Kun Liu	2016	75/F	occipital	42	pneumonia	negative
3	Shi Jie	2013	51/M	right thalamic	70	no	Staphylococcus
4	Santhosh	2009	57/M	right temporal	15	no	Escherichia coli
5	Shervin	2008	30/F	left basal ganglia	30	vasculitis	Escherichia coli
6	Olçay Eser	2008	1/F	right frontotemporal	2	no	Staphylococcus
7	Cheng XW	2007	56/M	left occipital	120	no	Staphylococcus
8	K. Nakai	2006	32/M	right temporoparietal	28	no	negative
9	Tianqing Liu	2003	54/M	right basal ganglia	5	no	negative
10	Nowak	2003	58/M	left thalamus	63	catheter-induced	Staphylococcus
11	Inamatsu J	2002	48/M	right putamen	30	pneumonia	Enterococcus
12	E.O.Amayo	2002	66/M	left putamen	30	pneumonia	negative
13	Okami	2000	51/M	left thalamus	unknown	no	Staphylococcus

Table 1: Case of brain abscess secondary to absorption stage of cerebral hemorrhage

The pathogenesis of brain abscess secondary to intracerebral hemorrhage is to destroy the blood-brain barrier (BBB), so that microorganisms are easy to deposit in the bleeding area, and then the formation of abscess^[8]. Disruption of the BBB by the hemorrhage may make the affected brain tissue susceptible to infection by blood-borne bacteria with subsequent abscess formation. Prompt treatment for brain abscess can show good results^[9]. Generally, surgical treatment followed with systemic antibiotic therapy (initially broad spectrum, then pathogen-targeted) can be the highest rate of success for this disease^[10]. Total abscess excision can also be adopted in patients with thick abscess capsule^[11].

In summary, There should be a high index of suspicion for a brain abscess following an intracerebral hemorrhage if the clinical and radiological picture differs from the expected course of a resolving hematoma^[12]. Appropriate surgical intervention followed with systemic antibiotic therapy is the best treatment option for this complicate disease^[13].

References

1. Ma T, Zhao ZL, Qi ZG. Cerebral hemorrhage with cerebral abscess: one case report. *Journal of Medical Imaging* 2018;28:857-61.
2. Liu K, Yang CX, Zhang YN. [Brain Abscess Following Intracerebral Hemorrhage in a Patient With Pneumonia. The Journal of Craniofacial Surgery](#) 2016;27:773-5.
3. Shi J, Liu H, Yang HY. Special imaging findings of 1 case of cerebral abscess complicated with cerebral hemorrhage absorption period. *China Medical Herald* 2013;10:99-100.
4. Santhosh GT, Ranjith KM, Vedantam R. [Brain abscess in a non-penetrating traumatic intracerebral hematoma: Case report and review of literature. Neurology India](#) 2009;57:73-5.
5. Shervin R, Dashti, Humain Baharvahdat. [Brain abscess formation at the site of intracerebral hemorrhage secondary to central nervous system vasculitis. Neurosurg Focus](#) 2008;24:1-4.
6. Olçay Eser, Murat Cosar, Adem Aslan. Intracerebral hematoma complicated with brain abscess in an infant. *Neurol Med Chir*

2008;48:176-8.

7. Cheng XW, Liu JM. A case report of multilocular brain abscess with cerebral hernia after hypertensive intracerebral hemorrhage. Chinese Journal of Modern Neurological Diseases 2007;7:263-4.

8. Nakai K, Yamamoto T, Yasuda S, et al. Brain abscess following intracerebral haemorrhage. Journal of Clinical Neuroscience 2006;13:1047-51.

9. Liu TQ. One case of cryptic brain abscess with cerebral hemorrhage as the first symptom. Journal of Hebei Medical College for Workers 2003;3:9-9.

10. Nowak DA, Rodiek SO, Topka H. Pyogenic brain abscess following

haematogenous seeding of a thalamic haemorrhage. Neuroradiology 2003;45:157-9.

11. Inamasu J, Kagami H, Nakamura Y, et al. Brain abscess developing at the site of preceding intracerebral hemorrhage. J Neurol 2002;249:221-3.

12. Amayo EO, Kwasa TO, Musau CK, et al. Primary intracerebral haemorrhage complicated by cerebral abscess: case report. East Afr Med J 2002;79:163-4.

13. Okami N, Kawamata T, Sasahara A, et al. Brain abscess following thalamic hemorrhage: a case report. No Shinkei Geka 2000;28:275-9, in Japanese.