

Short Communication

Open Access

## Warfarin Induced Skin Necrosis – Forgotten Diagnosis

Sachin Sondhi<sup>1\*</sup>, Ayushi Mehta<sup>2</sup>, Kunal Mahajan<sup>3</sup>

<sup>1</sup>Department of Cardiology, IGMC Shimla, HP, India

<sup>2</sup>Department of Anaesthesia, IGMC Shimla, HP, India

<sup>3</sup>Department of Cardiology, IGMC Shimla, HP, India

\*Corresponding Author: Sachin Sondhi, MD Medicine, DM Cardiology Fellow, Department of Cardiology, IGMC, Shimla, HP 171001, India. Tel: +91-8219508161, E-mail: [ssachin119@gmail.com](mailto:ssachin119@gmail.com)

**Citation:** Sachin Sondhi et.al. (2017), Warfarin Induced Skin Necrosis – Forgotten Diagnosis. Int J Car & Hear Heal. 1:1, 2-2

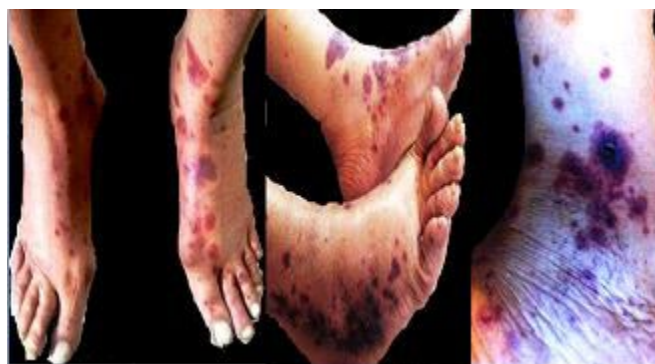
**Copyright:** ©2017 Sachin Sondhi et.al. This is an open-access article distributed under the terms of the Creative Commons Attribution License, which permits unrestricted use, distribution, and reproduction in any medium, provided the original author and source are credited

**Received** August 16, 2017; **Accepted** August 21, 2017; **Published** August 22, 2017

### Introduction

78 year old male presented to us with syncope and was found to have sick sinus syndrome in form of tachy-brady syndrome with intermittent atrial fibrillation. After pacemaker implantation, he was discharged on 3mg of warfarin for prevention of stroke. At time of discharge his baseline INR was 1.12. After 3 days of discharge, he developed painful ecchymosis over both lower limbs which progressed to hemorrhagic bullae and finally to eschar formation with central necrosis seen within 5 days (Figure 1). The INR at that time was 1.03. The diagnosis of Warfarin induced skin necrosis (WISN) was made. His warfarin was stopped for 4 days. After starting local wound care, lesions started improving. For stroke prevention, finally he was started on dabigatran 110mg twice a day.

**Figure 1.** WISN (a) 1st stage of burning painful ecchymotic areas over bilateral lower limb (b) 2nd stage showing hemorrhagic bullae (c) 3rd showing characteristic central necrosis



Skin necrosis occurs in 0.01% to 0.1% of patients receiving warfarin. Skin reactions associated with warfarin commonly occur 3 to 5 days after initiating treatment and are more common in protein C and protein S deficient patients. Warfarin inactivates vitamin K-dependent “clotting factors II, VII, IX, and X” and “natural anticoagulants, Proteins C and Protein S”. The Protein C and Protein S are inactivated immediately after starting warfarin because of short half life. This may cause a paradoxical hypercoagulable milieu in which microthrombi develop in cutaneous and subcutaneous microvasculature. This led to skin necrosis mostly over fatty areas. Treatment involves discontinuation of warfarin and reversal with vitamin K if needed. An alternative anticoagulant, such as heparin or LMWH, should be given to patients with thrombosis. Protein C concentrates may accelerate healing of skin lesion in protein C deficient patient; FFP may be value for those with protein S deficiency. Warfarin should be restarted at low doses with overlapping with parenteral anticoagulant and should be continued until the INR is in therapeutic range for at least 2 to 3 consecutive days.

### References

1. Gelwix TJ, Beeson MS. Warfarin- induced skin necrosis. Am J Emerg Med 1998;16:541-3.
2. Chan YC, Valenti D, Mansfield AO, Stansby G. Warfarin induced skin necrosis. Br J Surg 2000;87:266 – 72.
3. Sallah S, Abdalah JM, Gagnon GA. Recurrent warfarin-induced skin necrosis in kindreds with protein S deficiency. Haemostasis 1998;28:25 – 30.